

# Case Report

## Distraction Osteogenesis Treatment of Maxillary Deficiency for Cleft Patient Using Internal Distraction Device: A Case Report

Chutimaporn Keinprasit DDS, MS (Orthodontics)\*, Suthinun Danthumrongkul DDS\*,  
Thanasak Chengsuntisuk DDS\*\*, Thongchai Nuntanaranont DDS, MD\*\*\*

\* Department of Orthodontics, Faculty of Dentistry, Khon Kaen University, Khon Kaen, Thailand

\*\* Oral and Maxillofacial Surgery Unit, Dental Department, Khon Kaen Hospital, Khon Kaen, Thailand

\*\*\* Department of Oral and Maxillofacial Surgery, Faculty of Dentistry, Prince of Songkla University, Songkhla, Thailand

---

*A case of severe maxillary hypoplasia in a 21 years old male Thai patient with a complete unilateral cleft of primary and secondary palates treated by internal distraction osteogenesis for maxillary advancement is presented. Initial evaluation showed Class III malocclusion with total crossbite and Class III skeletal malrelationship. Two intraoral distractors were placed following a Le Fort I osteotomy. A maxillary advancement of 8 mms was obtained with 1 mm overjet. Following distraction, Class III elastics were used to increase the overjet until an overjet of 3 mms was obtained. Both acceptable skeletal and soft tissue relationships and satisfactory occlusion have been produced. After 20 months of postoperative follow-up, the occlusal result is stable and skeletal relapse can not be detected.*

**Keywords:** Distraction osteogenesis, Maxillary hypoplasia, Cleft lip and palate, Intraoral distraction device

**J Med Assoc Thai 2010; 93 (Suppl. 4): S83-S90**

**Full text. e-Journal:** <http://www.mat.or.th/journal>

---

Most cleft lip and palate patients demonstrate Class III skeletal problems due to maxillary hypoplasia with Class III malocclusion. There are techniques for treatment of these problems, such as growth modification during the growing period, orthognathic surgery for non-growing patients. In very severe cases, distraction osteogenesis is recommended in both children and adults.

### **Advantages and indications for maxillary distraction osteogenesis in cleft patients**

Distraction osteogenesis has been used in severe cleft patients since 1997<sup>(1)</sup>. A high Le Fort I osteotomy is usually performed for maxillary distraction because the maxillary hypoplasia is usually not restricted to the dento-alveolar segment, but involves the infraorbital, paranasal, and malar areas<sup>(2,3)</sup>. Advantages and indications for use of distraction osteogenesis are listed as follows:

1. In patients for whom conventional maxillary advancement with orthognathic surgery presents a disappointing result caused by excessive palatal and vestibular scarring after palatoplasty, or the already performed pharyngeal flaps for velopharyngeal insufficiency (VPI). These will restrain the maxillary advancement and affect the stability after surgery<sup>(2,4)</sup>.

2. In severe three dimensional maxillary deficiency: transverse, vertical and horizontal, which need advancement greater than 6 mms to 8 mms<sup>(2,5)</sup>.

3. Can be used in growing and non-growing patients<sup>(2,4)</sup>, young skeletal dysplasia can be treated without having to wait until skeletal maturity<sup>(2)</sup>.

4. Compared with the conventional Le Fort I osteotomy, the distraction operative morbidity is decreased while the amount of advancement is greater which affectively reduces concavity of facial profile<sup>(3)</sup>.

5. The stability of outcome is achieved by bone formation and enhanced by slow soft tissue expansion<sup>(4,5)</sup>.

6. New bone can be generated after distraction, both vertical and sagittal without grafting as it has to be done in orthognathic surgery<sup>(5,6)</sup>.

Generally, distraction osteogenesis of the

---

### **Correspondence to:**

Keinprasit C, Department of Orthodontics, Faculty of Dentistry,  
Khon Kaen University, Khon Kaen 40002, Thailand.  
Phone: 043-202-863, Fax: 043-202863  
E-mail: chutimap@kku.ac.th

maxillary cleft can be performed either by using external distraction devices (RED)<sup>(2,4,7,8)</sup> or intraoral devices<sup>(5,6,9)</sup>. Each has both advantages and disadvantages.

### **The rigid external distraction (RED) system**

The well known extraoral device for maxillary distraction is the rigid external distractor (RED). It consists of cranial halo which is placed parallel to Frankfurt horizontal plane, vertical bar to guide the halo position, horizontal bar that mounted with distraction screws and placed at the level to obtain the necessary vectors for the desired maxillary movement. An intraoral dental splint component is linked to the extraoral component by the screws that deliver the distraction forces<sup>(2)</sup>.

#### ***Specific benefits and precautions of the RED:***

1. The device is easy to install and remove<sup>(5)</sup>, there are no foreign bodies (*e.g.*, metallic plates, screws, or wires) left in the wound<sup>(3)</sup>.
2. The distraction vectors can be modified during the bone distraction<sup>(2,3,5)</sup>. Different distraction magnitude by different activation rates can be applied on the right and left side segments of the maxilla<sup>(3)</sup>.
3. Because the traction force is delivered through the teeth, the RED system needs a healthy dentition to support the device<sup>(3)</sup>. In case of multiple missing teeth or oligodontia, the RED system which requires anchorage teeth is not appropriate<sup>(9)</sup>. Osteointegrated implants or skeletal anchorage for the traction hooks are suggested in such cases<sup>(2)</sup>. The RED Leipzig retention plates is recommended as a bone-borne device<sup>(10)</sup>.
4. Since the RED halo-frame is conspicuous, it can create a physical and social inconvenience, resulting in low patient tolerance to wearing the external device for a long period<sup>(3,5)</sup>. The lack of compliance during the consolidation period may induce relapse<sup>(10)</sup>.
5. There is a tendency for the development of an anterior open bite when force is applied directly to the dentition, adequate control of the direction of traction with the appliance is needed<sup>(5)</sup>.
6. Patient cooperation is needed during the retention period of 4 to 6 months with a facemask after removal of the devices<sup>(9)</sup>, the undesirable mesial movement of the anchorage teeth cannot be prevented as a side-effect<sup>(7,11)</sup>.

### **Intraoral distraction device**

The intraoral or internal device on each side consists of an upper plate that is placed on the

zygomatic buttress and a lower plate that is anchored along the lateral maxillary wall below the transverse osteotomy<sup>(12)</sup>. The distractor is placed subperiostally directly on the bone and covered by facial or mucosal soft tissue. An activation port must exit transorally to avoid facial scar at the pin track site<sup>(13)</sup>. Forward maxillary advancement is achieved by turning the two distracted rods on the maxilla bilaterally<sup>(12)</sup>.

#### ***Specific benefits and precautions of the intraoral distraction devices:***

1. The intraoral devices are small, easy to handle and designed to produce sufficient stability during distraction and consolidation<sup>(13)</sup>. It does not require dental support to transfer the protraction forces because the devices are placed on bone<sup>(9)</sup>. They are less conspicuous and easier for patients to tolerate<sup>(5)</sup>, significantly reduce the amount of physical and psychological stress<sup>(9)</sup>. There is no extraoral device fixed to the craniofacial bone, this can reduce the length of the hospital stay<sup>(9)</sup>.
2. The devices do not leave scars caused by fixation screws compared with distraction osteogenesis with the RED system<sup>(9)</sup>.
3. It does not depend on patient cooperation during the retention period because the appliances are still fixed with the facial bone underneath the soft tissue<sup>(9)</sup>.
4. Intraoral distractors may perform insufficient distraction if there is not sufficient extension provided by the screws<sup>(6)</sup>.
5. Defective distraction vectors, especially with a unilinear distractor, can be produced while orthognathic surgery gives a definite amount and vector of movement<sup>(6)</sup>.
6. Because of the complex anatomy of the maxilla. It is difficult to place two distractors parallel to each other on each side of the maxilla and parallel to the sagittal plane<sup>(5,9)</sup>. The distraction vectors cannot be changed after the installation.
7. Excellent oral hygiene is essential because the distraction rods penetrate the mucosa in the mucobuccal fold. Local antibiotics can help to control any mucosal infections<sup>(13)</sup>.
8. An additional surgery is required to remove the devices<sup>(5,9)</sup>.

### **Case Report**

#### ***Case history:***

The patient was a 21 years old Thai male with a repaired right complete unilateral cleft lip and palate

with severe Class III malocclusion and very severe mid-facial hypoplasia. The cleft lip was repaired at the early infant period, and the cleft palate at four years of age. Secondary alveolar bone grafting was completed when he was 19. There was velopharyngeal insufficiency that produced hypernasal speech. Extraoral examination (Fig. 1) showed a symmetrical dolico-facial type with a concave profile and flat paranasal areas due to underdeveloped maxilla. The mandibular plane was steep. Intra-orally (Fig. 1), there was a pegged-shape lateral incisor in the lateral segment next to the cleft area. The occlusion was Class III with total crossbite and 6 mm negative overjet. There was an incomplete anterior bite with 0% vertical overlapping. Both maxillary first premolars and left maxillary first molars were missing with residual spaces. There was 3 mm crowding in the anterior region. Mandibular first molars were missing with the second molars drifted into the spaces. The lower dental midline was deviated 1 mm to the left. Cephalometric analysis showed a skeletal Class III relationship (ANB-6.5°) due to retrognathic maxilla (SNA 82.5°, A-Nperp -6 mm) and prognathic mandible (SNB 89°, Pog-Nperp +3 mm). Open vertical skeletal relationship (PP-MP 29.5°) was presented due to

anterior inclination of palatal plane (SN-PP 1.5°) and opening rotation of mandibular plane (SN-MP 31°), causing decreased facial index (73%). The incisors relative to their alveolar bone bases were retrusive and in upright position in both maxilla and mandible (Fig. 2, Table 1).

**Treatment:**

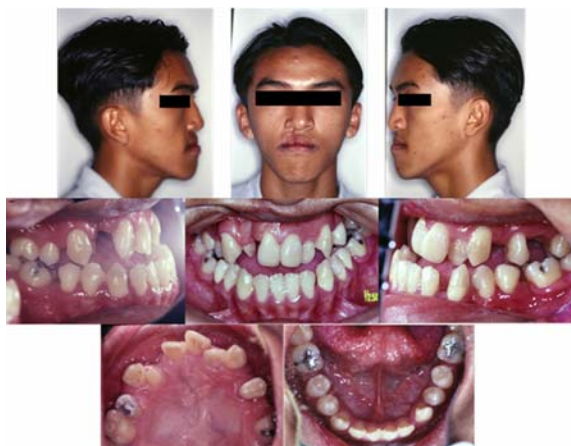The treatment plan was orthodontic treatment combined with maxillary distraction osteogenesis to correct skeletal discrepancy and improve facial appearance. Predistraction orthodontic treatment to level and align the dentition and close all edentulous spaces was planned. The objective of maxillary distraction is to advance and anterior-inferiorly reposition of the maxilla, so that mandibular set back would not be necessary to reduce its prognathism. After the distraction, treatment would be completed by finishing orthodontics.

The treatment was begun in early 2004 for arch leveling, aligning, space closures and inter-arch coordination. Predistraction orthodontic preparation was completed in 2007 as shown in Fig.3.

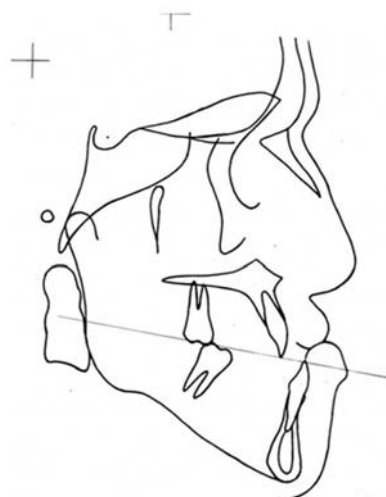
The surgical approach for distraction was

**Table 1.** Cephalometric measurements at pretreatment, posttreatment and 20 months posttreatment

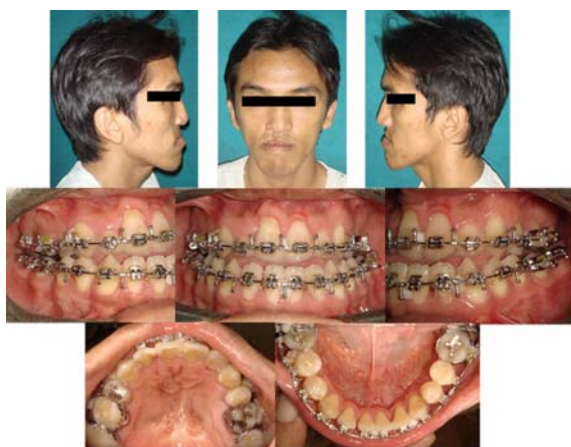measurements	Thai Norm	Pretreatment	Posttreatment	20 month in retention
SN-FH (degree)	7 ± 2.6	2	2	2
SNA (degree)	85.4 ± 4	82.5	89	88.5
A-N perp (mm)	4.3 ± 4.6	-6	0	-1
SNB (degree)	81 ± 3.7	89	85.5	85
Pog-N perp (mm)	0.3 ± 7	3.0	-3.0	-3.5
ANB (degree)	4 ± 2	-6.5	3.5	3.5
Wit appraisal (mm)	0 ± 5	-18	-5	-5
SN-MP (degree)	30 ± 5	31	36	36
SN-PP (degree)	8 ± 5	1.5	3.5	4
PP-MP (degree)	22 ± 5	29.5	32.5	32
Y-axis to FH (degree)	59 ± 3	61	64	64
Facial index (%)	81 ± 5	73	77	77
U1 to SN (degree)	107 ± 6	102	102	102
U1 to NA (degree)	21 ± 2	19	12	11.5
U1 to NA (mm)	4 ± 2	4.5	2	2
L1 to NB (degree)	30 ± 5	17	14	14.5
L1 to NB (mm)	7 ± 2	4	4	4
L1 to MP (degree)	97 ± 6	77	74	74.5
Interincisal angle (degree)	124 ± 7	150	151	150
Profile angle (degree)	163 ± 4	186	175	176
U lip to E-line (mm)	-1 ± 2	-6	-2.5	-3
L lip to E-line (mm)	1.5 ± 2	3	2.5	2.5
Nasolabial angle (degree)	110 ± 6.5	66	88	88.5



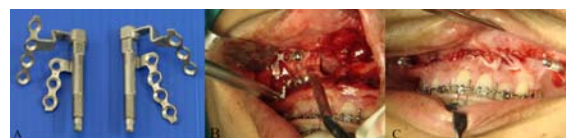**Fig. 1** Facial appearance and occlusion at start of treatment



**Fig. 2** Pretreatment lateral cephalogram prior to start of treatment demonstrates severe maxillary hypoplasia



**Fig. 3** Facial appearance and occlusion at predistraction orthodontic treatment



**Fig. 4** A: Internal distraction devices, Synthes®, B: Device placed between zygomatic buttress and maxillary alveolar bone base, C: The final position of distraction ports that penetrates the mucosa at the buccal vestibule

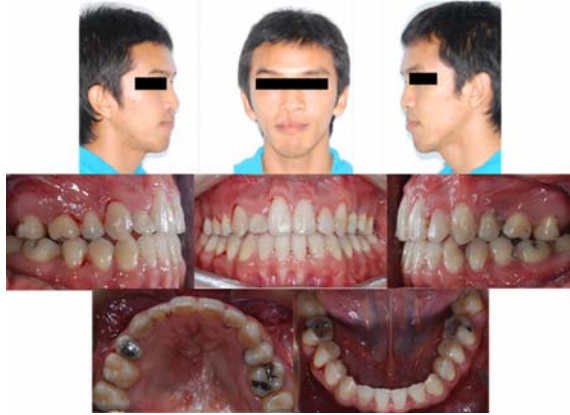similar to a Le Fort I osteotomy. Circumvestibular incision and complete osteotomy were performed and the maxilla was then down-fractured. Two intraoral distractors, Synthes<sup>®</sup> (Fig. 4A), were fixed in the desired orientation at the zygomatic buttresses and alveolar bone bases (Fig. 4B). The distraction vector was oblique to the occlusal plane to move the maxilla anteriorly and inferiorly. The devices were activated to test their function and the mobility of the released bone segment and then returned to the starting positions. The surgical wound was closed with the two activation ports exited through the mucosa into the buccal vestibules (Fig. 4C).

The device activation was started after a 5 days latency period. Both Synthes<sup>®</sup> screws were

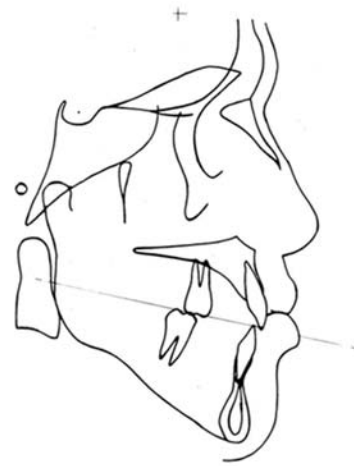activated by oral surgeons at a rate of 0.25 mm twice a day for 2 weeks and then 0.5 mm once a day for another week until 8 mms maxillary advancement with 1 mm positive overjet were obtained. After 4 months of complete bone consolidation, the distractors were removed and postdistraction orthodontic treatment was started. Intermaxillary Class III elastics were applied to produce 3 mms incisor overjet for overcorrection and prevention of anterior crossbite relapse. Satisfactory occlusion was achieved. There was no longer any posterior crossbite (Fig. 5). The orthodontic appliances were removed, and wraparound retainers were inserted in both arches in late 2007, 6 months after maxillary distraction consolidation period.

### Results

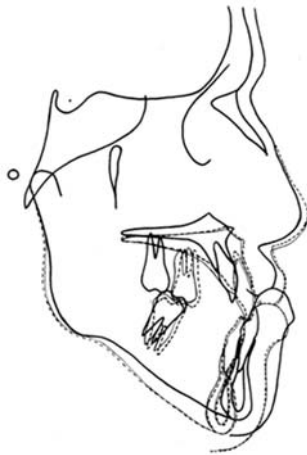The patient's skeletal pattern was changed from Class III to Class I relationship (ANB 3.5°) due to orthognathic maxilla (SNA 89°, A-Nperp 0 mm) and orthognathic mandible (SNB 85.5°, Pog-Nperp -3 mms),



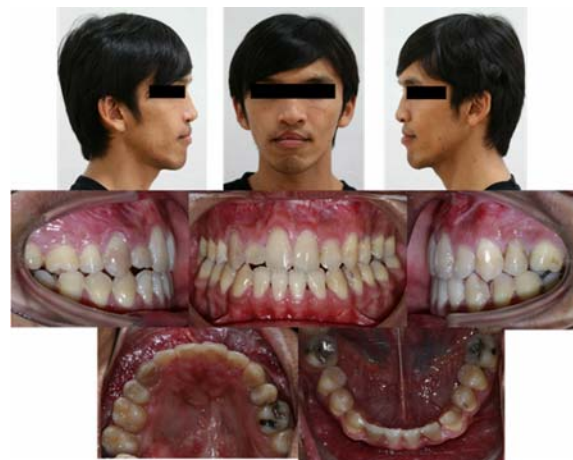**Fig. 5** Facial appearance and occlusion after orthodontic appliance removal



**Fig. 6** Posttreatment lateral cephalogram demonstrates normal antero-posterior skeletal relationship



**Fig. 7** Cephalometric superimposition, maxillary and mandibular movement and direction were compared, no skeletal relapse is observed  
 - pre-treatment (*dark solid line*)  
 - post-treatment (*dotted line*)  
 - 20<sup>th</sup> month retention phase (*light solid line*)



**Fig. 8** Retention period photographs, at 20 months after orthodontic appliance removal

the latter being associated with backward rotation of the mandible. The facial concavity was significantly improved (facial profile from 186° to 175°) (Table 1, Fig. 6). Acceptable upper lip position was achieved (U-lip to E-line from -6 mm to -2.5 mm). Cephalometric superimposition (Fig. 7) demonstrated maxillary and mandibular changes from the pretreatment to posttreatment and retention stages. The maxilla moved forward and downward. The prognathism of mandible was reduced. The patient was reviewed on the 3<sup>rd</sup>, 9<sup>th</sup>, 15<sup>th</sup> and 20<sup>th</sup> months of the retention period. No relapse was found both clinically and cephalometrically (Fig. 5, 8, 7 and Table 1).

### Discussion

At present, the correction of maxillary hypoplasia or severe Class III malocclusion in cleft patients is mostly performed by distraction osteogenesis. Because the health care program of the Thai National Health Security Office enabled support for the cost of osteotomy along with an anonymous third party for the high cost devices, it became feasible for the patient to have such sophisticated treatment of one jaw maxillary distraction which contributed great benefits in dealing with this patient's problems.

### Craniofacial deformities and treatment

Although cephalometrics of the patient shows

concave profile due to retrognathic maxilla and prognathic mandible (Fig. 2, Table 1), clinical examination clearly demonstrates severe retrusion of the maxilla with very flat paranasal areas, acute nasolabial angle with tipped downward nose and overclosure of the lower lip suggesting severe underdeveloped maxilla (Fig. 1). The patient's treatment was planned according to perceptions of desirable soft tissue features, more than to match cephalometric hard tissue norms. Instead of the treatment plan of two jaw surgery with maxillary advancement and mandibular set-back, maxillary distraction osteogenesis was performed to correct severe midfacial hypoplasia. With the oblique distraction movement to increase both antero-posterior and vertical dimensions, the one jaw distraction produced greater movement of the maxilla anteriorly. At the same time, inferior maxillary movement caused lower jaw autorotation and reduced mandibular prognathism. This approach provides the benefits of correction of the patient deformities without the risks and complication of the invasive two-jaw conventional orthognathic surgery and removing necessity for bone grafting.

The activation rate of distraction was initially set at 0.25 mm twice a day for two weeks because the patient found that 0.5 mm twice per day, as recommended by several authors<sup>(1,5,6,9,14)</sup>, was very painful of adjustments. For the following week, the pain disappeared and activation was continued at 0.5 mm once a day.

#### ***Velopharyngeal insufficiency and speech problems***

Despite the anterior distraction of the maxillary dento-alveolar segment and hard palate, there was no readily detectable worsening of the patient's nasalized speech and velopharyngeal insufficiency (VPI). The main reason for apparent absence of change could be that the speech was initially so poor that any increase in the velopharyngeal gap had only marginally adverse effect. In view of the patient's priority for improvement of facial appearance and, in any case, the decision that pharyngoplasty to correct the VPI and speech problem should be delayed, the maxillary distraction was carried out first.

#### ***Stability***

Distraction osteogenesis is superior to conventional orthognathic surgery for the stability of the results<sup>(2,4,13)</sup>. With conventional Le Fort I osteotomy advancement in cleft patients, the stability is considered as an unpredictable procedure with high relapse

rates<sup>(18)</sup>. In this case, after 20 months of postoperative follow-up, no relapse could be detected, either clinically (Fig. 5,8) or cephalometrically (Fig. 7 and Table 1). This matches results obtained in previous studies<sup>(11,13,19)</sup>. The maxilla moves slower but ultimately moves significantly more with distraction than by the conventional surgery where the maxillary repositioning is immediate but without soft tissue distraction. Distraction induces soft tissue adaptation and reduces relapse factors such as resistance of muscle, connective tissues, nerves, and skin that also undergo simultaneous distraction<sup>(6)</sup>.

#### **Conclusion**

Maxillary advancement by distraction osteogenesis is now frequently used to correct severe maxillary hypoplasia in cleft patients. The treatment outcome was successful. The intraoral distraction devices are simple and easy to use. They do not need patient cooperation and produce good results and good stability and reduce the chance of relapse. In addition, compared with conventional Le Fort I maxillary advancement, the intraoral distraction can prevent the increase of speech problems in a cleft patient who has velopharyngeal insufficiency. It helps to directly correct the patient's problems that they want to resolve. Good support from health care program is an important factor for this high cost sophisticated treatment.

#### **Acknowledgements**

The authors wish to thank the patient and Prof. Keith Godfrey for assistance with the English-language presentation of the manuscript.

#### **References**

1. Cohen SR, Burstein FD, Stewart MB, Rathburn MA. Maxillary-midface distraction in children with cleft lip and palate: a preliminary report. *Plast Reconstr Surg* 1997; 99: 1421-8.
2. Figueroa AA, Polley JW, Ko EW. Maxillary distraction for the management of cleft maxillary hypoplasia with a rigid external distraction system. *Semin Orthod* 1999; 5: 46-51.
3. Harada K, Baba Y, Ohyama K, Enomoto S. Maxillary distraction osteogenesis for cleft lip and palate children using an external, adjustable, rigid distraction device: a report of 2 cases. *J Oral Maxillofac Surg* 2001; 59: 1492-6.
4. Hierl T, Hemprich A. Callus distraction of the midface in the severely atrophied maxilla-a case report. *Cleft Palate Craniofac J* 1999; 36: 457-61.

5. Gateno J, Engel ER, Teichgraeber JF, Yamaji KE, Xia JJ. A new Le Fort I internal distraction device in the treatment of severe maxillary hypoplasia. *J Oral Maxillofac Surg* 2005; 63: 148-54.
6. Lauwers F, Mayorca-Guiliani A, Lopez R, Woisard-Bassols V, Paoli JR, Boutault F. Maxillofacial intraoral distraction osteogenesis followed by elastic traction in cleft maxillary deformity. *Int J Oral Maxillofac Surg* 2005; 34: 85-8.
7. Polley JW, Figueroa AA. Management of severe maxillary deficiency in childhood and adolescence through distraction osteogenesis with an external, adjustable, rigid distraction device. *J Craniofac Surg* 1997; 8: 181-5.
8. Uyanik LO, Karasu HA, Aytac D. The use of rigid external distraction for midface hypoplasia. Abstracts from the XVIII<sup>th</sup> Congress of the European Association for Cranio-Maxillofacial Surgery, 12-15 September 2006, Barcelona, Spain. *J Craniomaxillofac Surg* 2006; 34(Suppl 1): 155-6.
9. Kuroda S, Araki Y, Oya S, Mishima K, Sugahara T, Takano-Yamamoto T. Maxillary distraction osteogenesis to treat maxillary hypoplasia: comparison of an internal and an external system. *Am J Orthod Dentofacial Orthop* 2005; 127: 493-8.
10. Yamauchi K, Mitsugi M, Takahashi T. Maxillary distraction osteogenesis using Le Fort I osteotomy without intraoperative down-fracture. *Int J Oral Maxillofac Surg* 2006; 35: 493-8.
11. Figueroa AA, Polley JW. Management of severe cleft maxillary deficiency with distraction osteogenesis: procedure and results. *Am J Orthod Dentofacial Orthop* 1999; 115: 1-12.
12. Rachmiel A, Aizenbud D. Distraction osteogenesis in maxillary deficiency using intraoral devices. In: Bell WH, Guerrero CA, editors. *Distraction osteogenesis of the facial skeleton*. Hamilton: BC Decker; 2007: 16-20.
13. Kessler P, Wiltfang J, Schultze-Mosgau S, Hirschfelder U, Neukam FW. Distraction osteogenesis of the maxilla and midface using a subcutaneous device: report of four cases. *Br J Oral Maxillofac Surg* 2001; 39: 13-21.
14. Chin M, Toth BA. Distraction osteogenesis in maxillofacial surgery using internal devices: review of five cases. *J Oral Maxillofac Surg* 1996; 54: 45-53.
15. Kummer AW, Strife JL, Grau WH, Creaghead NA, Lee L. The effects of Le Fort I osteotomy with maxillary movement on articulation, resonance, and velopharyngeal function. *Cleft Palate J* 1989; 26: 193-9.
16. Janulewicz J, Costello BJ, Buckley MJ, Ford MD, Close J, Gassner R. The effects of Le Fort I osteotomies on velopharyngeal and speech functions in cleft patients. *J Oral Maxillofac Surg* 2004; 62: 308-14.
17. Alkan A, Bas B, Ozer M, Bayram M, Yuzbasioglu E. Maxillary anterior segmental advancement of hypoplastic maxilla in cleft patients by distraction osteogenesis: report of 2 cases. *J Oral Maxillofac Surg* 2008; 66: 126-32.
18. Ayliffe PR, Banks P, Martin IC. Stability of the Le Fort I osteotomy in patients with cleft lip and palate. *Int J Oral Maxillofac Surg* 1995; 24: 201-7.
19. Molina F, Ortiz Monasterio F, de la Paz Aguilar M, Barrera J. Maxillary distraction: aesthetic and functional benefits in cleft lip-palate and prognathic patients during mixed dentition. *Plast Reconstr Surg* 1998; 101: 951-63.

---

การยึดถ่างขยายกระดูกในผู้ป่วยปากแหว่งเพดานโหว่ที่มีการเจริญของขากรรไกรบนบกพร่องโดยใช้เครื่องมือยึดถ่างขยายกระดูกชนิดในช่องปาก: รายงานผู้ป่วยหนึ่งราย

ชุตติมาพร เขียนประสิทธิ์, ศุภธินันท์ ด่านธำรงกุล, ธนศักดิ์ เสงส์สันติสุข, ธงชัย นันทนรานนท์

ผู้ป่วยชายไทย อายุ 21 ปี มีการเจริญของขากรรไกรบนน้อยกว่าปกติอย่างรุนแรงร่วมกับมีภาวะปากแหว่งเพดานโหว่แบบสมบูรณ์เพียงด้านเดียว ได้รับการรักษา โดยใช้เครื่องมือชนิดใช้ในช่องปากยึดถ่างขยายกระดูกขากรรไกรบนออกมาทางด้านหน้า จากการประเมินเริ่มต้นพบว่า ผู้ป่วยมีการสบฟันผิดปกติชนิดที่ 3 ร่วมกับมีการสบคร่อมของฟันทั้งขากรรไกร และมีความสัมพันธ์ของขากรรไกรบนในแนวหน้า-หลังชนิดที่ 3 เครื่องมือยึดถ่างขยายกระดูกขากรรไกรชนิดใช้ในช่องปากจำนวน 2 ตัว ถูกนำมาใช้ร่วมกับการผ่าตัดขากรรไกรบนชนิดเลอฟอร์ต I ออสตีโอโตมี ผลการรักษาพบว่า เครื่องมือสามารถยึดถ่างกระดูกขากรรไกรบนออกมาทางด้านหน้าได้ 8 มิลลิเมตร โดยมีการสบเหลื่อมในแนวหน้าหลังของฟันหน้า 1 มิลลิเมตร ต่อจากนั้นใช้อีลาสติก ชนิดที่ 3 ดึงระหว่างฟันบนและฟันล่างเพื่อเพิ่มการสบเหลื่อมของฟันหน้าเพิ่มขึ้นเป็น 3 มิลลิเมตร ผู้ป่วยมีความสัมพันธ์ของโครงสร้างกระดูกใบหน้าเป็นที่ยอมรับได้ และมีการสบฟันที่น่าพึงพอใจ ในระยะเฝ้าติดตาม 20 เดือนภายหลังการรักษาเสร็จสิ้นพบว่าการสบฟันที่ได้มีเสถียรภาพ และไม่พบการคืนกลับของโครงสร้างกระดูกขากรรไกรที่ผิดปกติ

---