

Case Report

Early Maxillary Arch Changes in Complete Bilateral Cleft Lip and Palate: A Report of Four Cases

Chutimaporn Keinprasit DDS, MS*,
Chutinart Kuratchatchaval DDS*

* Department of Orthodontics, Faculty of Dentistry, Khon Kaen University, Khon Kaen, Thailand

Objective: To evaluate early maxillary arch changes in infants with complete bilateral cleft lip and palate (BCLP), using a simple measurement technique.

Material and Method: A measurement model technique simplified from previously reported methods was used to analyze early maxillary changes of four non-syndromic complete BCLP. Study models of these cases were evaluated before presurgical orthopedic treatment and lip reconstruction (T1) and prior to palatal closure (T2). Comparisons of maxillary arch changes were performed.

Results: At T1, protrusion with or without deviation of the primary palate and different amounts of cleft width were found. Anterior alveolar arch width was larger than the posterior. At T2, the primary palate was retracted and initial lateral displacement was corrected. Cleft widths were narrowed at all levels with the narrowest part located anteriorly, corresponding with the increasing of primary palate arch width. Posterior alveolar arch width was wider than the anterior region. Although the posterior alveolar arch was lengthened, total alveolar arch length was decreased which could be attributable to a large retraction of the primary palate.

Conclusion: Early morphological and positional changes to the three segments of maxillary arch could be visualized and clarified with this technique, using study models and arch form superimposition methods.

Keywords: Maxillary arch changes, Maxillary arch form, Bilateral cleft lip and palate

J Med Assoc Thai 2010; 93 (Suppl. 4): S91-S99

Full text. e-Journal: <http://www.mat.or.th/journal>

Patients with cleft lip and palate present with variable displacement of the maxillary alveolar segments at birth. In bilateral complete cleft lip and palate (BCLP) newborns, the primary palate is always in a protruded and upwardly rotated position and usually accompanied with deviation of the nasal septum⁽¹⁾. A broad maxillary arch with lateral displacement of the lateral segments has been reported^(2,3). This early segmental distortion in the newborns has been hypothesized as being due to interruption of circumoral and palatal musculature, and pressure from the tongue^(4,5).

Considering maxillary arch forms in the BCLP infants after lip reconstruction, an alteration of postoperative maxillary arch forms and dimensions has been reported^(1,2,6-12). The changes are due to many factors, not only the effect of surgical intervention^(6,8,9,12,13) but also the role of presurgical

orthopedics^(10,14,15), individual intrinsic growth potential^(6,10), and amount of palatal tissue deficiency due to the cleft deformity^(2,10,16).

Several investigation systems have been developed to assess arch forms and dimensions of the growing maxilla in both noncleft^(17,18) and cleft infants^(3,8,19). Most are two-dimensional (2-D) approach for model analysis. Recently, three-dimensional (3-D) technique has been advocated, aiming to explore the changed palatal cleft morphology^(20,21). There are authors who have asserted that when performing linear and angular measurements on landmarks which are located approximately at the same plane, 3-D analysis provides insignificant amounts of additional information compared to the 2-D method⁽²²⁾. Generally, the 2-D method is appropriate and widely used as a quick, reliable, and inexpensive model assessment in patients with cleft lip and palate^(3,8,15,19,22).

This report is aimed to evaluate early maxillary arch form of BCLP infants in both shape and dimensions using a simple measurement technique. Comparison of the maxillary arch changes prior to lip reconstruction (T1) and palatal closure (T2) of four

Correspondence to:

Keinprasit C, Department of Orthodontics, Faculty of Dentistry, Khon Kaen University, Khon Kaen 40002, Thailand.
Phone: 043-202-863, Fax: 043-202-863
E-mail: chutimap@kku.ac.th

BCLP cases are presented. The possible related factors that may influence on these findings are also discussed.

Material and Method

Four cases presented in this report were full-term non-syndromic complete BCLP who were treated at the Khon Kaen University Cleft and Craniofacial Center, Thailand. Study models of all subjects at two periods of time must be available for evaluation. The first ones (T1) were taken before presurgical orthopedic treatment, using obturator and extra-oral strapping following the method of Hotz⁽²³⁾, prior to lip reconstruction. The objectives of extra-oral strapping were to alter position of the protrusive primary palate and to facilitate lip reconstruction^(3,23). The other impressions (T2) were taken prior to palatal closure to allow an observation of maxillary arch changes.

Ages at T1 and T2 are different in all cases, they are: Case 1: T1 = six days, T2 = ten months; Case 2: T1 = 55 days, T2 = nine months; Case 3: T1 = 110 days, T2 = 11 months; Case 4: T1 = 115 days, T2 = 11 months. According to general timing protocol for presurgical orthodontic treatment⁽²³⁾, only the first two cases were treated within the recommended period of two months postnatally (Cases 1 and 2), while the others' treatments were delayed due to the inappropriate timing of referral to the Center. Effects of presurgical orthopedic treatment and different techniques of lip reconstruction on the maxillary arch changes are not separately identified and are not discussed in this report.

Methods of maxillary arch form investigation

On each dental casts, certain anatomical

landmarks based on the methods of Sillman⁽¹⁸⁾, Mazaheri and coworkers⁽¹⁹⁾, and Robertson and coworkers⁽³⁾ as described in Table 1 and margin of all parts of the primary palate, lateral segments and nasal septum were marked lightly with pencil. The models were then photocopied for arch measurements and superimposition of their tracings. Linear measurements as in Table 2 were performed, using a method modified from Mazaheri and coworkers⁽¹⁹⁾, Robertson and coworkers⁽³⁾, and Grabowski and coworkers⁽¹⁵⁾. The arch dimension components of widths were measured parallel to the intercanine line (CC') while lengths were estimated perpendicular to the same reference line (Fig. 1 and 2). Measurements were performed by a solitary investigator in random order twice, at a 2-week interval. In case of more than 0.5 mm or 0.5 degree difference between these two sets of measurements, a third measurement was made. The most extreme value was eliminated, and the arithmetic mean of the two remaining values was recorded.

Visual comparisons of maxillary arch changes were also performed by superimposition of photocopies at T1 and T2 on the reference intercanine line at mid-anterior alveolar arch width. Alterations of palatal morphology in sagittal and transversal planes in both direction and amount were observed with this technique.

Results

Photographs of maxillary models at T1, T2, and arch form superimpositions of each case are presented in Fig. 3A, B, C; 4A, B, C; 5A, B, C; and 6A, B, C. Linear maxillary arch measurements and comparisons at T1 and T2 of all cases are presented in Table 3.

Table 1. Anatomical landmarks and their definitions based on Sillman⁽¹⁸⁾, Mazaheri and coworkers⁽¹⁹⁾, and Robertson and coworkers⁽³⁾ (*denotes for the left side)

Point	Terminology	Definition
I	incisal	intersection between crest of the alveolar ridge and the line drawn from labial frenum to incisive papilla
C/C'	canine	intersection between crest of the alveolar ridge and the lateral sulcus
T/T'	tuberosity	intersection between crest of the alveolar ridge with outline of the tuberosity
P/P'	primary palate segment cleft edge	primary palate margin of cleft, on continuation with the line marking crest of the ridge
L/L'	anterior lateral segment cleft edge	lateral segment margin of cleft, on continuation with the line marking crest of the ridge
t/t'	posterior lateral segment cleft edge	intersection between the intertuberosity line and medial borders of cleft
M	mid-anterior arch width	midpoint of the intercanine distance

Table 2. Measurements and definitions modified from Mazaheri and coworkers⁽¹⁹⁾, Robertson and coworkers⁽³⁾, and Grabowski and coworkers⁽¹⁵⁾ for model analysis of BCLP infants (' denotes for the left side)

Measurements	Terminology	Definition
A. Width		
IM	primary palate deviation distance	distance from point I to M, parallel to CC' (+ if I point locates on the right of the M point and - if locates on the left)
LL'	anterior cleft width	distance from point L to L', parallel to CC'
tt'	posterior cleft width	distance from point t to t', parallel to CC'
PP'	primary palate arch width	distance from point P to P', parallel to CC'
CC'	anterior alveolar arch width	distance from point C to C'
TT'	posterior alveolar arch width	distance from point T to T', parallel to CC'
B. Length		
PL, P'L'	alveolar cleft length	distance from point P to L and P' to L', perpendicular to CC' (- if the lateral segment locates anteriorly to the primary palate or negative overlapping)
I-CC'	anterior alveolar arch length	perpendicular distance from point I to CC'
I-TT'	total alveolar arch length	distance from point I to TT', perpendicular to CC'

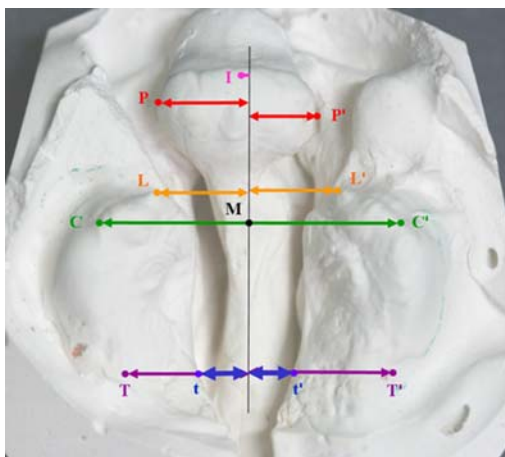


Fig. 1 Anatomical landmarks and width measurements of the study, all widths are made parallel to the intercanine line (' denotes for the left side):
 1.1 Primary palate deviation distance(IM)
 1.2 Anterior cleft width (LL')
 1.3 Posterior cleft width (tt')
 1.4 Primary palate arch width (PP')
 1.5 Anterior alveolar arch width (CC')
 1.6 Posterior alveolar arch width (TT')

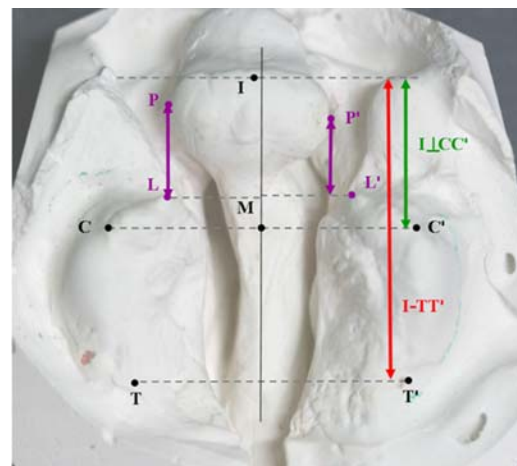


Fig. 2 Length measurements of the study are made perpendicular to the intercanine line (' denotes for the left side):
 1.1 Alveolar cleft length (PL/ P'L')
 1.2 Anterior alveolar arch length (I-CC')
 1.3 Total arch length (I-TT')

Discussion

Visual arch form analysis using superimposition method

During the first years of life, the greatest rate of normal alveolar growth can be identified at the posterior part of the arch as represented by increasing of the total arch length and posterior arch width⁽¹⁸⁾.

Increasing of the alveolar ridge length was occurred distally to the primary canine tooth buds while the anterior arch width was stabilized, altering the arch form into an elliptical shape in early postnatal period⁽¹⁾. Sillman (1964)⁽¹⁸⁾ also observed that growth in the dental arches usually precedes the eruption of the groups of teeth.

Based on these findings, superimposition of the arch form on the intercanine line (CC') at mid-anterior alveolar arch width can produce a visual

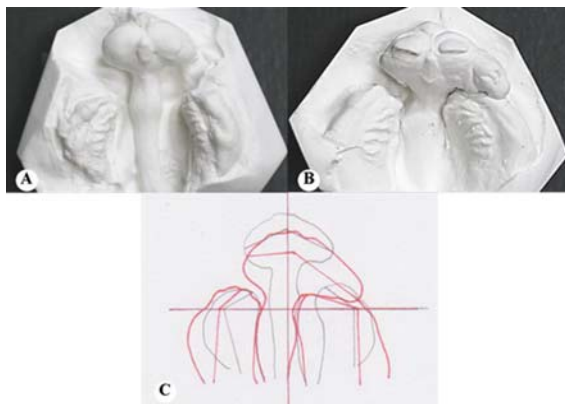


Fig. 3 Case 1 maxillary models of a female newborn:
 A: Age six days at T1, the primary palate was protruded at start of obturator with extra-oral strapping, four months prior to lip reconstruction.
 B: Age ten months at T2 (six months after lip reconstruction).
 C: Superimposition of maxillary cast photocopies at T1 (black line) and T2 (red line) on the reference intercanine line at mid-anterior alveolar arch width.




Fig. 4 Case 2 maxillary models of a female newborn:
 A: Age 55 days at T1, protrusion and deviation of the primary palate were obvious, an active presurgical orthopedic appliance with extra-oral strapping was used at a month prior to lip reconstruction
 B: Age nine months at T2 (six months after lip reconstruction)
 C: Superimposition of maxillary cast photocopies at T1 (black line) and T2 (red line) on the reference intercanine line at mid-anterior alveolar arch width

analysis of the entire morphological arch changes in both extent and direction. This reference plane also reduces an error from landmark identification at the tuberosity point which is considered as the most problematic landmark for arch measurements⁽²⁴⁾. Limitation of this technique is that superimposition on the intercanine line at the mid-anterior alveolar arch width should be used with caution in cases that abnormal anatomy of the primary palate is presented such as in Case 1 (Fig. 3C). Asymmetrical growth of the primary palate may interfere with growth of the anterior portion of the lateral segment from segmental overlapping, producing a transverse arch collapse and distortion of the canine point (C/C').

Alteration of the maxillary arch form and dimensions in the BCLP

1. Protrusion and deviation of the primary palate

Changes of the primary palate protrusion in this report was achieved by evaluating of the alveolar cleft lengths (PL, P'L'), anterior alveolar arch length (I-CC'), and visual comparison of the arch form superimposition (Table 3 and Fig. 3C, 4C, 5C and 6C). At T1, the primary palate is located anteriorly to the alveolar borders of the lateral segments with variety degrees of prominence and deviation similar to other previously reported studies^(2,3). Varied amounts of

anterior alveolar arch length (I-CC') reduction and approximately 30-45% of alveolar cleft length reduction allowed a more normal primary palate position to occur as shown in visual comparison of all cases.

Lateral deviation of the primary palate can be recognized by the primary palate deviation distance (IM). Deviation of the primary palate segment is usually associated with the bent nasal septum⁽¹⁾. This report also supports the finding that lateral deviations of the primary palate segment and nasal septum are apparent in Cases 2 and 3 (Table 3 and Fig. 4A and 5A). Interestingly, prior to the lip reconstruction, all cases except Case 1 had varied amounts of the primary palate deviation to the right which were later reduced to a more centered position as planned after the lip reconstruction. In fact, slight deviation of the primary palate to the left was observed at T2 (Table 3); however, it was negligible to be counted as clinically significant. With differences in the initial degree of primary palate deviation to the right and also patients' ages, it is hypothesized that the complete BCLP newborn has only the primary palate protrusion without deviation. Later developed divergence to the same right hand side in these cases may correlate with the initial amount of anterior cleft width (LL'), method and position of breast or bottle feeding. This is because lateral deviation of the primary palate was only found in

Table 3. Measurements at stage T1, T2, and the differences (T2-T1) (' denotes for the left side), ages are presented in parentheses

Variables	Case 1			Case 2			Case 3			Case 4		
	T1 (6 days)	T2 (10 mths)	T2-T1	T1 (55 days)	T2 (9 mths)	T2-T1	T1 (110 days)	T2 (11 mths)	T2-T1	T1 (115 days)	T2 (11 mths)	T2-T1
Width (mm)												
IM	0.5	-1.75	-2.25	4.25	-0.75	-5.00	6.25	-3.00	-9.25	0.25	-0.50	-0.75
LL'	17.50	16.25	-1.25	20.50	17.00	-3.50	20.50	19.50	-1.00	17.50	17.00	-0.50
tt'	14.50	9.50	-5.00	17.50	12.75	-4.75	15.00	*	*	9.00	8.00	-1.00
PP'	22.00	27.75	5.75	15.00	18.00	3.00	18.75	19.00	0.25	17.50	17.00	-0.50
CC'	31.50	33.25	1.75	35.25	31.50	-3.75	34.25	35.25	1.00	31.50	31.50	0
TT'	27.00	36.00	9.00	31.50	39.50	8.00	31.00	*	*	27.00	32.50	5.50
Length (mm)												
PL	10.50	7.75	-2.75	8.00	6.50	-1.50	11.00	7.00	-4.00	9.00	0.25	-8.75
P'L	8.50	-0.75	-9.25	11.25	5.00	-6.25	4.00	-2.00	-6.00	8.75	1.25	-7.50
I-CC'	19.75	14.00	-5.75	17.00	11.00	-6.00	17.25	10.00	-7.25	15.25	8.50	-6.75
I-TT'	34.25	34.00	-0.25	35.75	29.00	-6.75	34.25	*	*	33.75	26.50	-7.25

* TT', tt', and I-TT' could not be measured in Case 3 due to the tuberosity points being unable to be identified

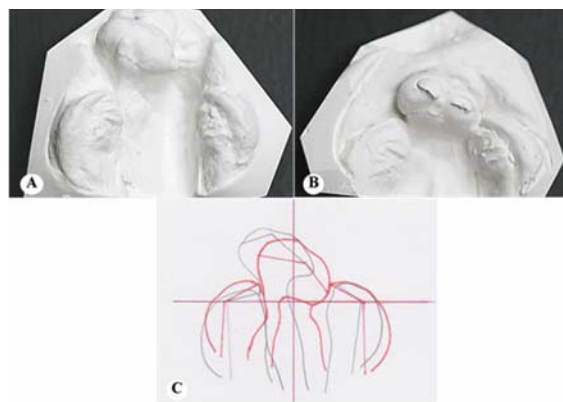


Fig. 5 Case 3 maxillary models of a female newborn:
A: Age 110 days at T1, the primary palate was protruded and deviated to the right at start of obturator with extra-oral strapping, three and a half months prior to lip reconstruction
B: Age 11 months at T2 (four months after lip reconstruction)
C: Superimposition of maxillary cast photocopies at T1 (black line) and T2 (red line) on the reference intercanine line at mid-anterior alveolar arch width

patients with wide anterior cleft width of more than 20 mm. Position and stiffness of the teat during feeding may easily produce such deviation. A larger number of samples is required to test this hypothesis.

Comparing the primary palate position at T1 and T2 with the arch form superimpositions, previous deviation of the primary palate was improved, allowing a more symmetrical arch form at the anterior region after the lip was closed. These changes have been claimed to be results of a molding action and pressure from reconstructed lip^(6,12) and the effect of presurgical orthopedic and extra-oral strapping⁽¹²⁾.

2. Relationship of the primary palate arch width (PP') and anterior cleft width (LL')

Varied amounts of anterior cleft width (LL') were observed at T1. Anterior cleft width is larger than the primary palate arch width (PP') in most cases except one (Case 1) that abnormal anatomy of the primary palate was presented (Fig. 3A). This situation created a transverse segmental overlap. Large deviation of the primary palate and the nasal septum can produce a transverse overlap of the alveolar segments on the deviated side as well (Fig. 4A and 5A).

At T2 stage, compared to the T1, PP' increased in most cases except that of Case 4 which was maintained (Table 3), producing an appearance of a flatter and broader primary palate as observed by

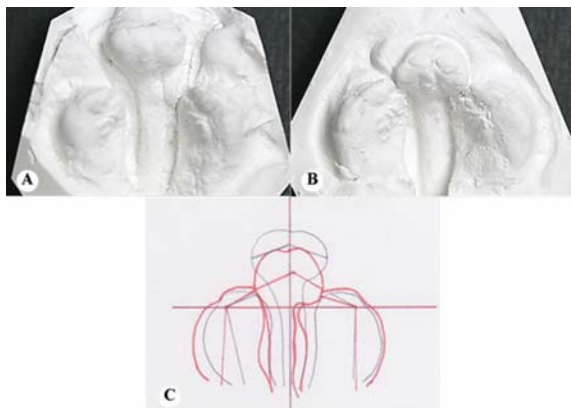


Fig. 6 Case 4 maxillary models of a female newborn:
 A: Age 115 days at T1, protrusion of the primary palate was apparent, an obturator with extra-oral strapping was used prior to lip reconstruction for approximately three months
 B: Age 11 months at T2 (four months after lip reconstruction)
 C: Superimposition of maxillary cast photocopies at T1 (black line) and T2 (red line) on the reference intercanine line at mid-anterior alveolar arch width

Heidbuchel and colleagues (1998)⁽¹²⁾. The PP' and LL' at this stage were then almost the same size. Combined with the posterior reposition of the primary palate after lip reconstruction, an end-to-end contact relationship between the primary palate and the lateral segments which may prevent further overlapping of the alveolar segments⁽⁶⁾ was established at 11 months of age before palatal closure (Fig. 5B and 6B). There was one case (Case 1) that segmental overlapping still existed from the continuing growth of the primary palate on the left side which may correlate with the presence or eruption of the lateral incisor (Fig. 3B)⁽⁷⁾. Further growth of these segments may even increase the amount of trapping and maintain condition of maxillary arch collapse.

3. Relationship of the anterior alveolar arch width (CC') and anterior cleft width (LL')

Prior to the lip surgery, anterior alveolar arch width may be affected by the distance or amount of anterior cleft width. It seems that the greater the anterior cleft width, the wider the anterior parts of the lateral alveolar arch segment widths (Cases 2 and 3). This finding agrees with the reported greater alveolar arch width in the BCLP infants than the noncleft newborns^(1-3,8). Distortions of the maxillary segments and the widening of both cleft width and alveolar arch

width in the BCLP are related to absence of traction of circumoral muscles^(1,25) and interruption of muscular sling orientation around the soft palate^(5,8). Pressure from the tongue also plays a role on the anterior alveolar arch width as the tongue is forced into the cleft site, establishing and maintaining an imbalanced environment which subsequently displaces and widens the maxillary segments^(1,6,25). Interestingly, despite a younger age of Case 2 at T1 (55 days), the sizes of the alveolar segments were quite equivalent to those of Case 3 (110 days). This finding may be related to the differences of individual intrinsic growth potential and postnatal nutritional status. Serial observation of the maxillary arch changes accompanied by changes of weight and length individually is required to clarify this postulate.

After the lip was closed at T2, various patterns of the anterior alveolar arch width changes were observed in the superimposition as it was maintained (Fig. 6C), widened (Figs. 3C, and 5C), or even narrowed (Fig. 4C). Normally, increasing of the anterior arch width is the most preferable situation for two reasons: it may prevent further segmental overlap after palatal closure, and may provide more space to match with growth of the primary palate arch width⁽¹¹⁾. Anterior alveolar arch width that is increased or maintained signifies that narrowing of the anterior cleft width at the T2 stage may be a result of medial growth at the anterior portion of the lateral segments. These conditions were found in most cases of the study (Table 3). On the other hand, decrease of anterior alveolar arch width while the anterior cleft width was also narrowed as shown in Case 2 indicates that reduction of the anterior cleft width may be due to a medial collapse of the lateral segments rather than a medial growth of the alveolar segments.

Superimpositions of the arch form at T1 and T2 represent a noticeable growth of the lateral segments as their overall sizes or boundaries were increased (Fig. 3C, 4C, and 6C). The entire cleft widths from anterior to posterior were also narrowed in all cases with the narrowest part located at the level of the CC' line. Reduction of the cleft width at all levels after lip reconstruction is claimed due to a molding action from the restored muscle matrix, medial growth of the lateral segments and reduced inclination of the palatal shelves^(8,19).

Early maxillary arch changes at the anterior alveolar region during T2 stage which are reduction of the anterior cleft width (LL'), alveolar cleft length (PL, P'L'), and anterior alveolar arch length (I-CC') may be

the result of several influencing factors. The principal factor is the lip molding effect from lip reconstruction^(9,10,12,13,26). Proper restoration of the lip can produce a balanced function of the circumoral muscles and soft tissue which is essential for development of the normal arch form in the cleft infants^(9,10,12,13,25,26).

Relationship of the posterior alveolar arch width (TT') and posterior cleft width (-tt')

At T1, the posterior alveolar arch width was always smaller than the anterior alveolar arch width and it became larger at the time before palatal closure (T2) which is corresponded to those of other findings^(1,8,11) (Table 3). This larger of the posterior alveolar arch width than the anterior arch width was also observed in the nonclefts⁽¹⁸⁾. Superimposition of the arch forms at T1 and T2 showed that posterior portion of the lateral segments was widened laterally. Interestingly, this widening of the posterior arch width did not increase the cleft width at posterior region; instead it was narrowed as presented in the arch form superimpositions. Reduction of the posterior cleft width in these cases could be explained by appositional bone growth of the palatal shelves along the cleft margins^(7,19). Aduss and Pruzansky in 1968 reported that size and shape of the inferior turbinate might play an important role on the alveolar arch width and cleft width⁽⁷⁾. They showed that cleft width would be further narrowed until the nasal septum had a broad contact with the inferior turbinates. A small and flattened medial surface of the inferior turbinate would allow more medial approximation of the lateral segments to occur. Alteration of the tongue position following the downward and forward mandibular growth which subsequently allows the palatal shelves growth may be another factor that influences on reduction of the posterior cleft width as well⁽⁶⁾.

Relationship of the anterior alveolar arch length (I-CC') and total alveolar arch length (I-TT')

Reduction of the total alveolar arch length was observed in all cases at T2 stage. This finding is mainly caused by more retropositioning of the primary palate after the lip was reconstructed.

Superimposition of the arch forms at T1 and T2 reveals that there is an apparent appositional growth of the maxillary arch posteriorly to the CC' plane in all cases. Although the tuberosity points could not be clearly identified in some cases, active growth of the lateral segments posteriorly to the CC' plane was more

obvious than the anterior as their borders are widened and lengthened. This finding is identical to a previous study⁽¹⁾ and also similar to that of nonclefts⁽¹⁸⁾. In cases that excessive retracting force from either lip surgery or the labial strapping against the primary palate is presented, sagittal growth at the tuberosity may compensate for over-reduction of the anterior alveolar arch length or even maintain the total arch length after lip reconstruction⁽⁹⁾.

Conclusion

A method for analysis of early maxillary arch growth in infants with BCLP is presented. Initial models of the gum pads were obtained approximately three months before lip reconstruction, and follow-up models at approximately six months later just prior to palatal closure. Changes of position and morphology of the primary palate, along with changes in maxillary arch widths and antero-posterior arch lengths, were recorded using linear measurements and superimposition of the maxillary arch model photocopies. To observe the maxillary arch changes and the possible related factors in the complete BCLP infants more properly, further prospective longitudinal study with a larger number of subjects would be required.

Acknowledgements

The authors would like to express their gratitude to Prof. Keith Godfrey for his assistance with manuscript preparation.

References

1. Kramer GJ, Hoeksma JB, Pahl-Andersen B. Early palatal changes in complete and incomplete cleft lip and/or palate. *Acta Anat (Basel)* 1992; 144: 202-12.
2. Huddart AG. Maxillary arch dimensions in bilateral cleft lip and palate subjects. *Cleft Palate J* 1970; 7: 139-55.
3. Robertson N, Shaw W, Volp C. The changes produced by presurgical orthopedic treatment of bilateral cleft lip and palate. *Plast Reconstr Surg* 1977; 59: 87-93.
4. Delaire J. The potential role of facial muscles in the monitoring maxillary growth and morphogenesis. In: Carlson DS, McNamara JA Jr, editors. *Muscle adaptation in craniofacial region*. Ann Arbor, MI: Center for Human Growth and Development, University of Michigan; 1978: 157-80.
5. Latham RA. The development, structure and growth pattern of the human mid-palatal suture. *J*

- Anat 1971; 108: 31-41.
6. Pruzansky S. Factors determining arch form in clefts of the lip and palate. *Am J Orthod* 1955;41:827-51.
 7. Aduss H, Pruzansky S. Width of cleft at level of the tuberosities in complete unilateral cleft lip and palate. *Plast Reconstr Surg* 1968; 41: 113-23.
 8. Harding RL, Mazaheri M. Growth and spatial changes in the arch form in bilateral cleft lip and palate patients. *Plast Reconstr Surg* 1972; 50: 591-9.
 9. Kramer GJ, Hoeksma JB, Prah-Andersen B. Palatal changes after lip surgery in different types of cleft lip and palate. *Cleft Palate Craniofac J* 1994; 31: 376-84.
 10. Honda Y, Suzuki A, Ohishi M, Tashiro H. Longitudinal study on the changes of maxillary arch dimensions in Japanese children with cleft lip and/or palate: infancy to 4 years of age. *Cleft Palate Craniofac J* 1995; 32: 149-55.
 11. Opitz C, Kratzsch H. Maxilla dimension in patients with unilateral and bilateral cleft lip and palate. Changes from birth until palate surgery at age three. *J Orofac Orthop* 1997; 58: 110-23.
 12. Heidbuchel KL, Kuijpers-Jagtman AM, Van't Hof MA, Kramer GJ, Prah-Andersen B. Effects of early treatment on maxillary arch development in BCLP. A study on dental casts between 0 and 4 years of age. *J Craniomaxillofac Surg* 1998; 26: 140-7.
 13. Bardach J. The influence of cleft lip repair on facial growth. *Cleft Palate J* 1990; 27: 76-8.
 14. Chan KT, Hayes C, Shusterman S, Mulliken JB, Will LA. The effects of active infant orthopedics on occlusal relationships in unilateral complete cleft lip and palate. *Cleft Palate Craniofac J* 2003; 40: 511-7.
 15. Grabowski R, Kopp H, Stahl F, Gundlach KK. Presurgical orthopaedic treatment of newborns with clefts-functional treatment with long-term effects. *J Craniomaxillofac Surg* 2006; 34(Suppl 2): 34-44.
 16. Coupe TB, Subtelny JD. Cleft palate deficiency or displacement of tissue. *Plast Reconstr Surg* 1960; 26: 600-12.
 17. Ashley-Montagu MF. The form and dimensions of the palate in the newborn. *Int J Orthod* 1934; 20: 694-704.
 18. Sillman JH. Dimensional changes of the dental arches: longitudinal study from birth to 25 years. *Am J Orthod* 1964; 50: 824-42.
 19. Mazaheri M, Harding RL, Cooper JA, Meier JA, Jones TS. Changes in arch form and dimensions of cleft patients. *Am J Orthod* 1971; 60: 19-32.
 20. Kriens O. Data-objective diagnosis of infant cleft lip, alveolus, and palate. Morphologic data guiding understanding and treatment concepts. *Cleft Palate Craniofac J* 1991; 28: 157-68.
 21. Mishima K, Sugahara T, Mori Y, Sakuda M. Three-dimensional comparison between the palatal forms in complete unilateral cleft lip and palate with and without Hotz plate from cheiloplasty to palatoplasty. *Cleft Palate Craniofac J* 1996; 33: 312-7.
 22. Braumann B, Rosenhayn SE, Bourauel C, Jager A. Two- or three-dimensional cast analysis in patients with cleft lip and palate? *J Orofac Orthop* 2001; 62: 451-65.
 23. Hotz M, Gnoinski W. Comprehensive care of cleft lip and palate children at Zurich university: a preliminary report. *Am J Orthod* 1976; 70: 481-504.
 24. Seckel NG, van der Tweel I, Elema GA, Specken TF. Landmark positioning on maxilla of cleft lip and palate infant-a reality? *Cleft Palate Craniofac J* 1995; 32: 434-41.
 25. Delaire J. Theoretical principles and technique of functional closure of the lip and nasal aperture. *J Maxillofac Surg* 1978; 6: 109-16.
 26. Mazaheri M, Harding RL, Nanda S. The effect of surgery on maxillary growth and cleft width. *Plast Reconstr Surg* 1967; 40: 22-30.

การศึกษาการเปลี่ยนแปลงของสันเหงือกขากรรไกรบนในทารกที่มีภาวะปากแหว่งเพดานโหว่แบบสมบูรณ์
ทั้งสองด้าน: รายงานผู้ป่วย 4 ราย

ชุตินาพร เขียนประสิทธิ์, ชุตินารถ คุรัตน์ชัชวาล

วัตถุประสงค์: เพื่อศึกษาถึงการเปลี่ยนแปลงของสันเหงือกขากรรไกรบนในทารกที่มีภาวะปากแหว่งเพดานโหว่แบบสมบูรณ์ทั้งสองด้าน ด้วยวิธีการวัดแบบจำลองสันเหงือกอย่างง่าย

วัสดุและวิธีการ: ทำการวิเคราะห์การเปลี่ยนแปลงของสันเหงือกขากรรไกรบนด้วยวิธีการจากวิธีการวัดในอดีตในแบบจำลอง สันเหงือกของทารกที่มีภาวะปากแหว่งเพดานโหว่แบบสมบูรณ์ทั้งสองด้านชนิดไม่มีกลุ่มอาการร่วมจำนวน 4 ราย โดยวิเคราะห์เปรียบเทียบการเปลี่ยนแปลงที่เกิดขึ้นในระยะก่อนได้รับการบำบัดทางทันตกรรม เพื่อลดการยื่นของเพดานปรัสมภูมิร่วมกับการทำศัลยกรรมผ่าตัดเสริมสร้างเพื่อแก้ไขภาวะปากแหว่ง (T1) และระยะก่อนการผ่าตัดเพื่อแก้ไขภาวะเพดานโหว่ (T2)

ผลการศึกษา: ในระยะ T1 พบการยื่นซึ่งอาจร่วมกับการเอียงตัวของเพดานปรัสมภูมิ และพบความกว้างของช่องโหว่ในปริมาณที่แตกต่างกัน ความกว้างของส่วนโค้งสันเหงือกส่วนหน้ากว้างกว่าความกว้างของส่วนโค้งสันเหงือกส่วนหลัง ในระยะ T2 พบว่าเพดานปรัสมภูมิมีการเคลื่อนตัวถอยหลังโดยไม่พบการเอียงตัวไปทางด้านข้าง ความกว้างของช่องโหว่ลดลงในทุกระดับโดยส่วนที่แคบที่สุดอยู่บริเวณด้านหน้าของขากรรไกรสัมพันธ์กับความกว้างของเพดานปรัสมภูมิที่เพิ่มขึ้น ความกว้างของส่วนโค้งสันเหงือกส่วนหลังเพิ่มขึ้นมากกว่าส่วนหน้า แม้ว่าส่วนโค้งสันเหงือกส่วนหลังจะมีความยาวเพิ่มขึ้นความยาวทั้งหมดของส่วนโค้งสันเหงือกกลับลดลง ซึ่งเกิดจากเพดานปรัสมภูมิมีการเคลื่อนตัวถอยหลังอย่างมาก

สรุป: การเปลี่ยนแปลงรูปร่างและตำแหน่งของสันเหงือกขากรรไกรบนทั้งสามส่วนในทารกสามารถแสดงให้เห็นได้ชัดเจนด้วยวิธีการวัดแบบจำลองสันเหงือกและการซ้อนทับรูปภาพส่วนโค้งของขากรรไกรบน
