

Case Report

Orthodontic Treatment Combined with Orthognathic Surgery and Simultaneous Alveolar Bone Graft of a Unilateral Complete Cleft Lip and Palate Patient: A Case Report

Poonsak Pisek DDS, MSc, FRCDT, MOrth, RCSEd*,
Montian Manosudprasit DDS, MDS, FRCDT*, Tasanee Wangsrimongkol DDS, MS, PhD*,
Suthin Jinaporntham DDS, MD, Dr.Med, FRCDT**, Opas Wiwatworakul DDS*

* Department of Orthodontics, Faculty of Dentistry, Khon Kaen University, Khon Kaen, Thailand

** Department of Oral and Maxillofacial Surgery, Faculty of Dentistry, Khon Kaen University, Khon Kaen, Thailand

This article aimed to present a case of 22 year-old Thai female with cleft lip and palate who had malocclusion developed from dental problems, skeletal disharmony and unrepaired alveolar cleft. The treatment was orthodontic combined with one-stage surgical correction which corrected skeletal discrepancy and alveolar cleft in single operation. After treatment, the patient had improved in facial esthetics, attaining good occlusal function and continuous maxillary dental arch. This procedure can reduce morbidity, preclude a second hospitalization and the cost of two-stage surgical correction. However, this is only an alternative treatment for adult cleft patients who need late alveolar bone graft and orthognathic surgery.

Keywords: Cleft lip and palate, Orthodontic treatment, Orthognathic surgery, Simultaneous alveolar bone graft

J Med Assoc Thai 2015; 98 (Suppl. 7): S225-S233

Full text. e-Journal: <http://www.jmatonline.com>

Cleft lip and palate is a common congenital malformation. The incidence is different among races, however this condition affects about 1 to 2 per 1,000 live births⁽¹⁾. The cleft lip and palate patients generally present with many problems and need a multidisciplinary approach which requires many healthcare specialists beyond plastic surgeons and dentists⁽²⁾. Therefore, many centers have developed their protocol to manage cleft patients from birth to adults in order to achieve overall optimal results⁽³⁻⁵⁾.

Despite many centers utilizing a multidisciplinary approach to manage cleft patients, some of them still have residual defects until adulthood. Repair of cleft lip and secondary palate is usually performed during infancy and early childhood, respectively. Alveolar cleft is usually corrected by iliac bone graft procedure before permanent canine eruption⁽³⁻⁵⁾. The canine which erupts through a bone grafted area will maintain bone volume and reduce bone

graft resorption⁽⁶⁾. There is, however, an adverse effect to maxillary growth and some of cleft patients will require orthognathic surgery⁽⁷⁾. Le fort I maxillary osteotomy procedure is normally needed to advance maxilla with or without mandibular surgery to correct skeletal discrepancy.

Some cleft lip and palate patients are not able to receive treatment at the optimal time. For example, the alveolar bone graft procedure is not carried out at mixed dentition before permanent maxillary canine eruption and the unrepaired alveolar cleft remains until adulthood. These patients usually present with poor oral hygiene, malocclusion, skeletal discrepancy, unrepaired alveolar cleft and oronasal fistula. The treatment approach may, therefore, differ for these patients. There are two treatment options for these patients. The first option is orthodontic treatment with alveolar bone grafting followed by maxillary osteotomy. This option needs two-stage surgical treatment. To avoid second surgery and hospitalization, another possible treatment is orthodontic treatment with orthognathic surgery and simultaneous alveolar bone graft in single operation^(8,9).

The purpose of this article was to report the treatment of 22 year-old female who had undergone

Correspondence to:

Suthin J, Department of Oral and Maxillofacial Surgery, Faculty of Dentistry, Khon Kaen University, Muang, Khon Kaen 40002, Thailand.

Phone: +66-89-6174352

E-mail: jsuthin@hotmail.com

repair of unilateral cleft lip and palate since childhood, yet she still had unrepaired alveolar cleft with skeletal class III malocclusion. The treatment was orthodontic treatment combined with orthognathic surgery and simultaneous alveolar bone graft.

Case Report

A 22 year-old female presented with a difficulty chewing problem due to her anterior teeth and protruded chin. She had left unilateral complete cleft lip and palate and her otherwise general health was good. She had undergone repair of her left unilateral complete cleft lip at the age of three months, followed by a repair of the cleft palate by the age of one year.

Clinical examination

The facial profile was concave with retrognathic maxilla and prognathic mandible. She had incompetent lip at rest with retruded upper lip and protruded lower lip. In frontal view, she had asymmetrical ovoid face due to deviation of her chin to the right side, depressed left alar of nose and scar of a repaired upper lip. The facial proportion revealed a slight

increase of the lower third of the face (Fig. 1).

Intra-oral examination

She had poor oral hygiene with a multiple loss of teeth due to pulpal diseases including missing of tooth 22. The maxillary dental arch form was collapsed and presented a left alveolar cleft between teeth 21 and 23 with oronasal fistula. The occlusion showed anterior and bilateral posterior crossbite. Angle's classification cannot be indentified due to loss of all permanent first molars, absence of lateral incisors, the upper canines moved forward and nearly contacted with the central incisors. She had 6.5 mm negative overjet and 1 mm overbite. The upper dental midline was 1 mm deviated toward the right side whereas the lower dental midline coincided with facial midline. The arch length discrepancies in maxillary and mandibular dental arches were -3 mm and 4 mm, respectively. Tooth 15 was rotated and in palatal position. Tooth 38 showed caries with pulp exposure. There was no canting of occlusal plane and CO-CR discrepancy (Fig. 2).

Radiographic examination

The panoramic film showed an alveolar cleft at left maxillary dental arch and multiple tooth loss. There was neither embedded nor supernumerary tooth, but the left mandibular third molar impaction with large dental caries and a periapical lesion were noted (Fig. 3A).

From lateral cephalometric analysis, it revealed skeletal class III due to retrognathic maxilla and prognathic mandible ($FH-NA = 88^\circ$, $FH-NPog = 91^\circ$, $ANB = -3^\circ$) with hyperdivergent ($FH-MP = 29^\circ$). The maxillary incisors showed normal inclination and position related to maxillary alveolar bone base ($U1-SN = 98^\circ$, $U1-NA = 22^\circ$, 4 mm). The mandibular incisors had a retroclination, but showed a normal position as related to the mandibular alveolar bone base ($L1-MP = 76^\circ$, $L1-NB = 16^\circ$, 7 mm). The facial profile was concave with retruded upper lip and protruded lower lip (Fig.

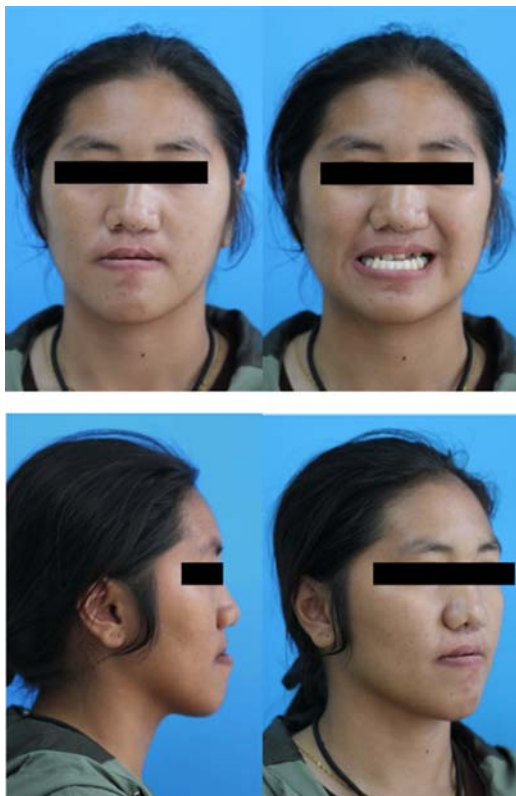

Fig. 1 Pre-treatment extra-oral photographs.

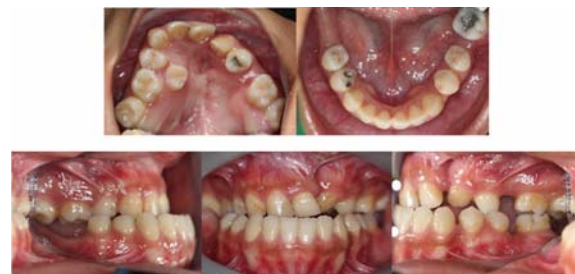

Fig. 2 Pre-treatment intra-oral photographs.

3B).

The occlusal film showed a large alveolar bone cleft of the left maxilla extending to the left nasal cavity. The adjacent teeth tipped toward the cleft (Fig. 3C).

The treatment objectives

Corrections of malocclusion in this case aimed for attaining good function, stability, health and esthetic. Since the malocclusion of this patient was developed from dental problems, unrepaired alveolar cleft and skeletal discrepancies, the treatments were orthodontic combined with orthognathic surgery and simultaneous alveolar bone graft. To avoid dental prosthesis as much as possible, orthodontic tooth movement was decided for space closure. Even though the tooth component on the left mandibular dental arch did not correlate with left maxillary dental arch, a dental prosthesis was still needed at this area. The enameloplasty as well as composite restoration were required for shaping substituted tooth.

Treatment

After control of oral hygiene and extraction of teeth 15 and 38, full fixed orthodontic appliances were bonded. The arch wires started with 0.014" NiTi

and progressing to 0.019x0.025 SS, which were used for leveling and aligning the teeth position and dental arches. The maxillary incisors were kept in position whilst the retroclined mandibular incisors were proclined and decompensated. All spaces at upper and lower dental arches were closed by moving posterior teeth forward. The upper and lower dental arches were coordinated and the deviated upper dental midline was corrected.

The mandibular incisors were tipped labially leading to increased lower incisors to mandibular plane (L1 to MP) about 10 degree angles whilst the inclination and position of maxillary incisors were constant. There were no changes in SNA, SNB and ANB. The skeletal vertical dimension was maintained (Fig. 11 and Table 1). The overjet was -8 mm and the overbite was 1 mm. The facial esthetic looked slightly more severe due to orthodontic decompensation (Fig. 4-6).

The skeletal class III relationship was corrected by Le fort I maxillary osteotomy to advance the maxilla and bilateral sagittal split ramus osteotomy and in order to set the mandible back. The maxillary

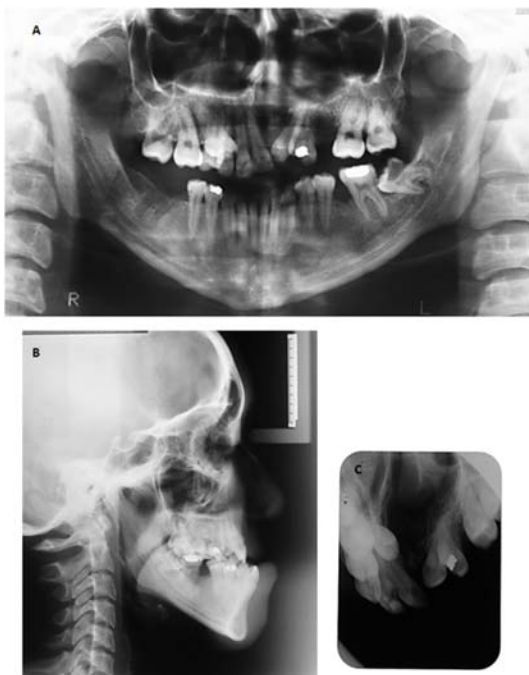

Fig. 3 Pre-treatment radiographs: A) panoramic radiograph, B) lateral cephalometric radiograph, C) occlusal radiograph.

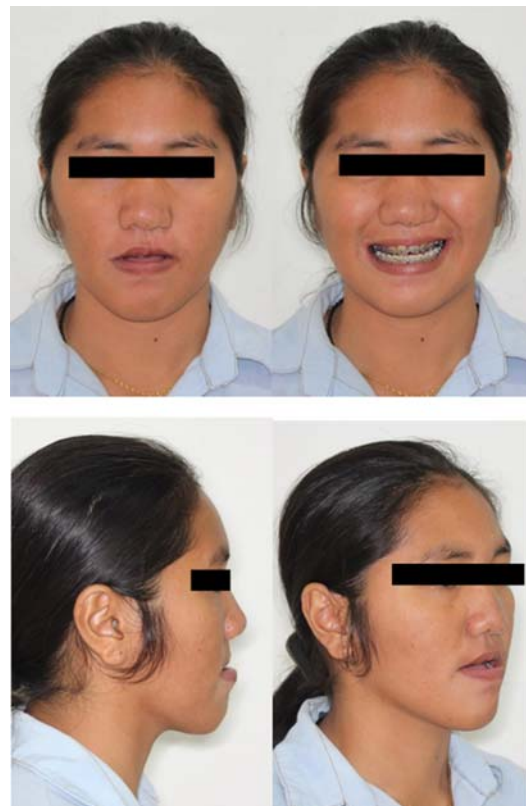

Fig. 4 Extra-oral photographs after pre-surgical orthodontic treatment.

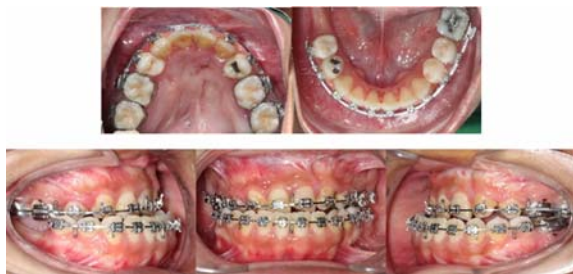

Fig. 5 Intra-oral photographs after pre-surgical orthodontic treatment.

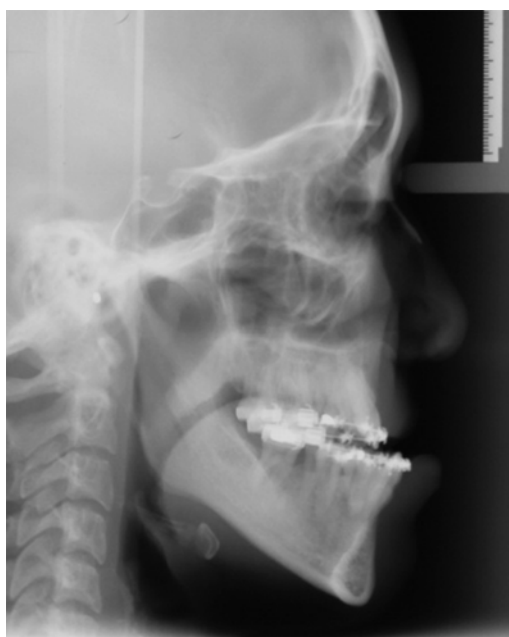

Fig. 6 Lateral cephalometric radiograph after presurgical orthodontic treatment.

and mandibular osteotomies were stabilized with rigid fixation by miniplates and screws. The alveolar cleft was grafted by autogenous bone taken from iliac crest. All of these procedures were performed in one operation.

For weeks after the operation, the orthodontic treatment was continued. After six months, the final occlusion was detailed and finished by 0.017x0.025" SS. The wrap around retainers were delivered and recommended full time wearing. The patient was referred to restorative and prosthodontic clinics for shaping substituted teeth and lower removable partial denture.

Treatment outcomes

Post-treatment photographs showed

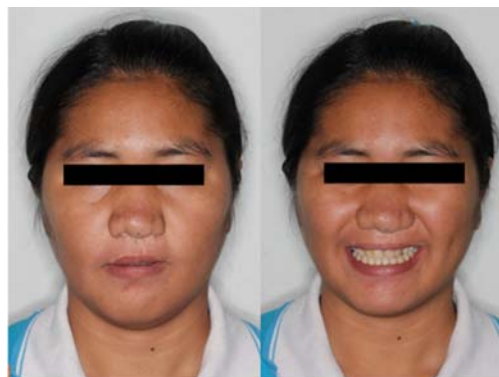

Fig. 7 Post-treatment extra-oral photographs.

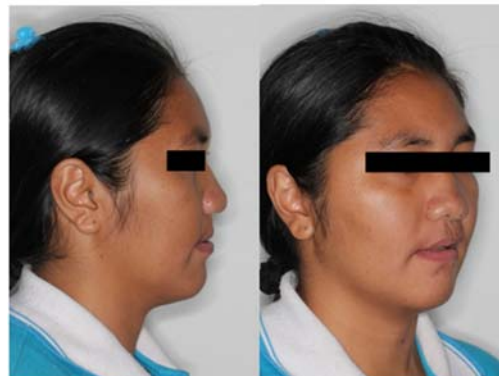
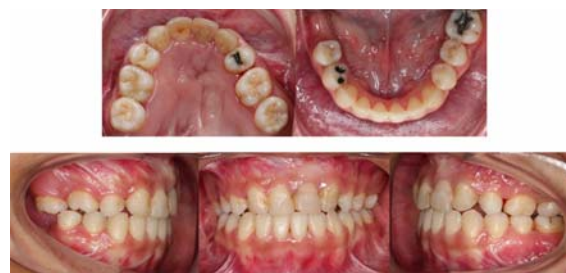
Fig. 8 Post-treatment intra-oral photographs.



improvement of facial appearance, smile and facial profile. The upper and lower lips positions were normal and harmonious to each other. Normal nasolabial angle was remained. The final occlusion was acceptable with normal overjet (2 mm) and overbite (1.5 mm) and desirable buccal occlusion was attained. The upper and lower dental midline were coincide with the facial midline. The alveolar cleft and all spaces were closed. However, tooth shaping and dental prosthesis were still needed (Fig. 7, 8).

The occlusal radiograph which was taken three months after operation showed filling of bone in

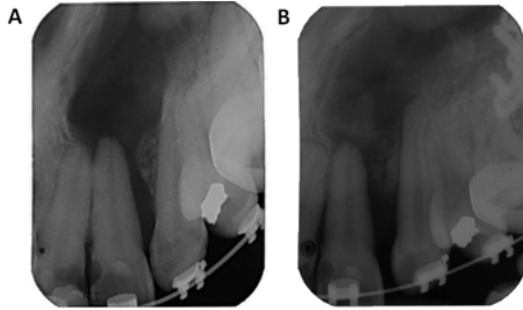


Fig. 9 Periapical radiographs: A) pre-surgical alveolar bone cleft, B) three months after the alveolar bone graft.

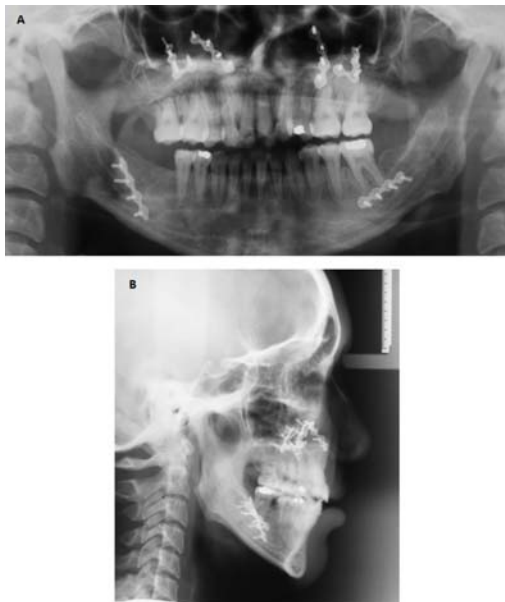


Fig. 10 Post treatment radiographs: A) panoramic radiograph, B) lateral cephalometric radiograph.

the alveolar bone cleft to level of the middle third of the root (Fig. 9).

The post-treatment lateral cephalometric radiograph and superimposition (Fig. 10B, 11 and Table 1) showed SNA angle increased from 77° to 79° whilst SNB angle decreased from 80° to 75° . This contributed to improvement of maxillomandibular relationship presented by changing of ANB angle from -3° to 3° . The mandibular plane angle (SN-MP and FMA) was slightly increased. The maxillary incisors were maintained whilst the mandibular incisors were proclined. The most important treatment outcome was the significant improvement in facial convexity (changed from 184° to 172°). The upper and lower lips

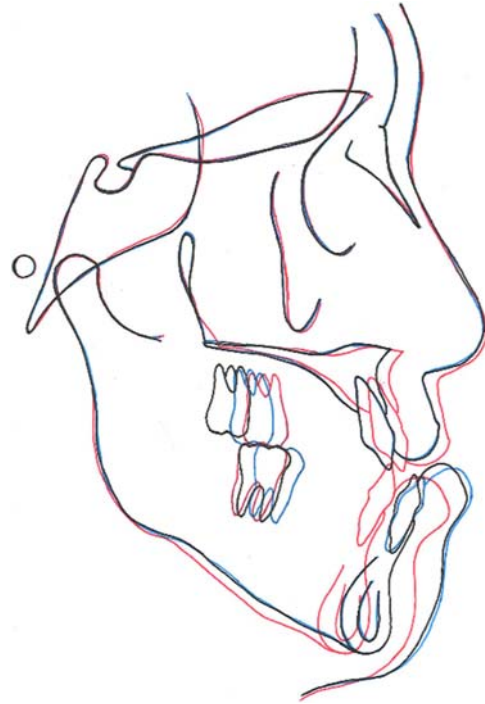


Fig. 11 Cephalometric superimposition: black line = pre-treatment; blue line = during treatment before surgery; and red line = post-treatment.

were improved in their positions and relationships. The post-treatment panoramic radiograph showed acceptable root parallelism without signs of bone or root resorption (Fig. 10A).

Discussion

Malocclusion as a main problem in cleft patients may be developed from dental anomaly, alveolar cleft defect and skeletal disharmony between maxilla and mandible⁽¹¹⁾. These conditions need treatments with suitable time as suggested by the protocol. However, the prevalence and extent of residual deformities vary widely depending on the stage of treatment. This patient, who lost dental follow-ups since the age of six, presented with loss of teeth, malocclusion, unrepaired alveolar cleft and skeletal disharmony between maxilla and mandible. Considering cost-risk benefits, the treatment was done by orthodontic combined with orthognathic surgery and simultaneous alveolar cleft bone grafting. After treatment, the patient achieved a balanced facial esthetic and continuity of maxillary dental arch. The final occlusion was acceptable with normal overjet and overbite.

Any alveolar cleft should be considered for

Table 1. Cephalometric measurements

	Measurements	Thai norm	Pre-treatment	During-treatment	Post-treatment
Skeletal	SN length (mm)	70±4	72	72	72
	SN-FH (°)	7±2.58	10	10	10
	SNA (°)	84±3.58	77	77	79
	SNB (°)	81±3.59	80	80	75
	ANB (°)	3±2.50	-3	-3	3
	FH-NA (°)	94±3.5	88	88	89
	FH-NPog (°)	90±3	91	91	86
	A-N perpend (female) (mm)	0.4±2.3	-3	-3	0
	Pog-N perpend (female) (mm)	-1.6±4.5	1	1	-4
	SN-MP (°)	30±5.61	40	40	41
	FH-MP (10)	22.7±5.4	29	29	31
Dental	U1-SN (°)	108±6.13	98	98	100
	U1-NA (°)	22±5.94	22	22	18
	U1-NA (mm)	5±2.13	4	4	3
	L1-MP (°)	97±5.97	76	86	80
	L1-NB (°)	30±5.61	16	25	19
	L1-NB (mm)	7±2.22	7	9	5
Soft tissue	U1-L1 (°)	125±8.03	145	137	139
	Profile angle (°)	168.7±4*	184	184	172
	Nasolabial angle (°)	91±7.98	88	88	95
	U-lip to E-line (mm)	-1±2	-7.5	-7.5	-4
	L-lip to E-line (mm)	2±2.03	3	4	1
	Ls to SnV (mm)	1-2*	4	4	3
	Li to SnV (mm)	-1-0*	-11	-13	3

* Represent Caucasian norm

alveolar bone graft. Aims for this procedure are to allow tooth eruption to the alveolar cleft area and provide possibility of orthodontic tooth movement into this area. The additional benefits and objectives of this treatment include maxillary segments stabilization, closure of oronasal fistula closing, providing bony support for alar base and nasal asymmetry improvement⁽¹²⁾.

The timing for alveolar bone graft is an important issue. The primary alveolar bone graft, which was carried out within the first two years of age, aims to stabilize maxillary segments early to prevent dental distortion and collapse. However, this procedure leads to impair maxillary growth and usually results in crossbite and a poor dental arch form⁽¹³⁻¹⁵⁾. Moreover, there may be inadequate bone formation and a need for additional bone graft⁽¹⁶⁾. A secondary alveolar bone graft usually performs before canine eruption or its root have developed 1/2 to 2/3 of its length^(16,17). This timing is advocated an optimal treatment time because the canine will erupt through graft site and stabilize the

bone, and subsequently, reduce the risk of alveolar bone graft resorption⁽¹⁸⁾. Transverse maxillary growth is nearly complete at the age of eight, this procedure, therefore, has no adverse effect on maxillary growth^(19,20). Even though this patient underwent late secondary alveolar bone graft after canine eruption, orthodontic tooth movement, which acts as functional force, can keep bone graft from disuse atrophic resorption⁽²¹⁾.

Alveolar bone graft technique can be combined with other surgical procedure. Stoelting and colleagues⁽²¹⁾ suggested that if orthodontic treatment alone cannot contribute to satisfactory dental arch alignment, segmental osteotomy should be incorporated to correct the deformities. The segmental maxillary osteotomy can facilitate 3-dimensional reposition of the collapsed maxillary segments. This procedure also allows approximation of the segments and reduces the need for replacement of congenital missing tooth. After repositioning of the collapsed segments, bone graft will be carried out in order to unite the fragments. Samman et al⁽²²⁾ compared outcomes of conventional

alveolar bone graft method with those who underwent simultaneous maxillary osteotomies with alveolar bone graft. The overall outcomes of standard alveolar bone graft method were better than the simultaneous maxillary osteotomy cases. However, the outcomes of the latter group were acceptable when compared with other published studies that operated standard alveolar bone grafting without osteotomies^(17,23).

Despite adequate treatments following the protocol recommended by many centers, some patients developed some degree of maxillary hypoplasia. A study by Ross⁽⁷⁾ showed that 25% of cleft patients necessitate maxillary osteotomy. Thus, cleft lip and palate patients usually develop skeletal class III malocclusion. Maxillary advancement by Le Fort I maxillary osteotomy is the most common procedure to correct retrognathic maxilla. Some patients may require additional procedures such as bilateral sagittal split ramus osteotomy to set the mandible back. Although Le Fort I maxillary osteotomy has been widely performed, maxillary advancement is sometimes difficult and limited, especially in cases with severe maxillary hypoplasia. Distraction osteogenesis has been advocated to increase distance for maxillary advancement, improve stability and reduce the risk of velopharyngeal insufficiencies⁽²⁴⁾.

Some adult cleft lip and palate patients may present with residual problems. These include skeletal class III malocclusion due to maxillary hypoplasia with or without mandibular hyperplasia, residual oronasal fistula, alveolar cleft, bony defect and dental anomaly. These conditions are very challenging for the clinicians. A possible treatment would be orthodontic treatment with fistula closure and alveolar bone graft followed by later orthognathic surgery. Nevertheless, this two-stage approach is not cost-effective because the patient has to be hospitalized and undergo a second operation under general anesthesia. Subsequently, the patient has to be at risk from general anesthesia and complications twice. Some general anesthetic complications are nausea and vomiting, injury to teeth, anaphylaxis, aspiration pneumonia, and etc⁽²⁵⁾. Moreover, frequent hospitalizations are not good for growing patients educationally and socially, and its cost increases. A better treatment is one-stage surgical correction of these residual problems. The skeletal discrepancy, oronasal fistula and alveolar cleft were corrected at the same time. This treatment option can be applied for both unilateral and bilateral cleft lip and palate patients^(8,9,26-29). Ponsnick et al^(8,9) reported successful treatment of simultaneous alveolar bone graft with orthognathic surgery in almost all cases.

There were only three of 40 cases in UCLP and five of 22 cases in BCLP which still remained with oronasal fistula. The positive overjet and overbite were maintained in almost all cases for greater than one year of follow-up. However, post-surgical relapse is commonly occurred after maxillary advancement especially in cleft lip and palate patients^(29,30). Cheung et al⁽²⁷⁾ suggested that using miniplate fixation can reduce post-surgical relapse of cleft patients who underwent Le Fort I maxillary osteotomy with simultaneous alveolar bone grafting. Nonetheless, Erbe et al⁽²⁸⁾ stated that the miniplate fixation just reduces the period of inter-maxillary fixation and they suggested placing the palatal cuts laterally to the cleft in order to avoid palatal scar contracture and improve the stability.

The major advantage of Le Fort I maxillary osteotomy with simultaneous alveolar bone graft is allowing correction of skeletal discrepancy, oronasal fistula and alveolar cleft gap at the same time. The overall morbidities and costs are reduced with successful outcomes⁽³¹⁾. This procedure can claim cost effectiveness for healthy, adult cleft patients who have had maxillary hypoplasia and alveolar cleft with oronasal fistula^(8,9). Surgeons, however, should have experience. There should be care with soft tissue management and blood supply to the soft tissue and maxillary segments during operation. Moreover, controlling the maxillary segments and rigid fixation of these segments are crucial for the healing of bone graft and for long-term stability.

Conclusion

Orthognathic surgery with simultaneous alveolar bone graft is a one-stage procedure that corrects not only skeletal discrepancy but also alveolar cleft and oronasal fistula in a single operation. However, this is only an alternative treatment for cleft patients who need late alveolar cleft bone graft and orthognathic surgery. This procedure cannot replace standard protocol that alveolar cleft bone graft should be performed before permanent canine eruption to achieve optimal outcomes. For adult cleft lip and palate patients who have skeletal discrepancy with alveolar cleft, this one-stage treatment procedure is cost-effective. The morbidity and cost are reduced, and the result is satisfactory.

What is already known on this topic ?

The treatment protocols for cleft lip and palate patients were developed by many centers. A secondary alveolar bone graft is typically performed before permanent canine eruption. Orthognathic surgery is

usually operated when growth has been completed. However, some cleft patients cannot receive treatment at this optimal period.

What this study adds ?

For adult cleft lip and palate patients who have a skeletal discrepancy with alveolar cleft, orthognathic surgery with simultaneous alveolar bone graft in a single-stage treatment procedure is an alternative treatment.

Acknowledgement

The authors wish to thank the patient for her co-operation during treatment. In addition, thanks to the Faculty of Dentistry, Khon Kaen University and to the Center of Cleft Lip-Cleft Palate in association with the “Tawanchai Project”.

Potential conflicts of interest

None.

References

1. Vanderas AP. Incidence of cleft lip, cleft palate, and cleft lip and palate among races: a review. *Cleft Palate J* 1987; 24: 216-25.
2. Robin NH, Baty H, Franklin J, Guyton FC, Mann J, Woolley AL, et al. The multidisciplinary evaluation and management of cleft lip and palate. *South Med J* 2006; 99: 1111-20.
3. Chowchuen B, Keinprasit C, Pradubwong S. Primary unilateral cleft lip-nose repair: the Tawanchai cleft center’s integrated and functional reconstruction. *J Med Assoc Thai* 2010; 93 (Suppl 4): S34-45.
4. Hodgkinson PD, Brown S, Duncan D, Grant C, McNaughton A, Thomas P, et al. Management of children with cleft lip and palate : A review describing the application of multidisciplinary team working in this condition based upon the experiences of a regional cleft lip and palate centre in the united kindom. *Fetal Matern Med Rev* 2005; 16: 1-27.
5. Nahai FR, Williams JK, Burstein FD, Martin J, Thomas J. The management of cleft lip and palate: Pathways for treatment and longitudinal assessment. *Semin Plast Surg* 2005; 19: 275-85.
6. Enemark H, Sindet-Pedersen S, Bundgaard M. Long-term results after secondary bone grafting of alveolar clefts. *J Oral Maxillofac Surg* 1987; 45: 913-9.
7. Ross RB. Treatment variables affecting facial growth in complete unilateral cleft lip and palate. *Cleft Palate J* 1987; 24: 5-77.
8. Posnick JC, Tompson B. Modification of the maxillary Le Fort I osteotomy in cleft-orthognathic surgery: the unilateral cleft lip and palate deformity. *J Oral Maxillofac Surg* 1992; 50: 666-75.
9. Posnick JC, Tompson B. Modification of the maxillary Le Fort I osteotomy in cleft-orthognathic surgery: the bilateral cleft lip and palate deformity. *J Oral Maxillofac Surg* 1993; 51: 2-11.
10. Young ND, Nagarajan N, Lin SJ, Korhonen PK, Jex AR, Hall RS, et al. The *Opisthorchis viverrini* genome provides insights into life in the bile duct. *Nat Commun* 2014; 5: 4378.
11. Santiago PE, Grayson BH. Role of the craniofacial orthodontist on the craniofacial and cleft lip and palate team. *Semin Orthod* 2009; 15: 225-43.
12. Amanat N, Langdon JD. Secondary alveolar bone grafting in clefts of the lip and palate. *J Craniomaxillofac Surg* 1991; 19: 7-14.
13. Eppley BL, Sadove AM. Management of alveolar cleft bone grafting—state of the art. *Cleft Palate Craniofac J* 2000; 37: 229-33.
14. Trotman CA, Long RE Jr, Rosenstein SW, Murphy C, Johnston LE Jr. Comparison of facial form in primary alveolar bone-grafted and nongrafted unilateral cleft lip and palate patients: intercenter retrospective study. *Cleft Palate Craniofac J* 1996; 33: 91-5.
15. Friede H, Johanson B. Adolescent facial morphology of early bone-grafted cleft lip and palate patients. *Scand J Plast Reconstr Surg* 1982; 16: 41-53.
16. Bajaj AK, Wongworawat AA, Punjabi A. Management of alveolar clefts. *J Craniofac Surg* 2003; 14: 840-6.
17. Bergland O, Semb G, Abyholm FE. Elimination of the residual alveolar cleft by secondary bone grafting and subsequent orthodontic treatment. *Cleft Palate J* 1986; 23: 175-205.
18. Dempf R, Teltzrow T, Kramer FJ, Hausamen JE. Alveolar bone grafting in patients with complete clefts: a comparative study between secondary and tertiary bone grafting. *Cleft Palate Craniofac J* 2002; 39: 18-25.
19. Levitt T, Long RE Jr, Trotman CA. Maxillary growth in patients with clefts following secondary alveolar bone grafting. *Cleft Palate Craniofac J* 1999; 36: 398-406.
20. Semb G. Effect of alveolar bone grafting on maxillary growth in unilateral cleft lip and palate patients.

- Cleft Palate J 1988; 25: 288-95.
21. Stoelinga PJ, Haers PE, Leenen RJ, Soubry RJ, Blijdorp PA, Schoenaers JH. Late management of secondarily grafted clefts. Int J Oral Maxillofac Surg 1990; 19: 97-102.
 22. Samman N, Cheung LK, Tideman H. A comparison of alveolar bone grafting with and without simultaneous maxillary osteotomies in cleft palate patients. Int J Oral Maxillofac Surg 1994; 23: 65-70.
 23. Freihofer HP, Borstlap WA, Kuijpers-Jagtman AM, Voorsmit RA, van Damme PA, Heidbuchel KL, et al. Timing and transplant materials for closure of alveolar clefts. A clinical comparison of 296 cases. J Craniomaxillofac Surg 1993; 21: 143-8.
 24. Cheung LK, Chua HD. A meta-analysis of cleft maxillary osteotomy and distraction osteogenesis. Int J Oral Maxillofac Surg 2006; 35: 14-24.
 25. Aitkenhead AR. Injuries associated with anaesthesia. A global perspective. Br J Anaesth 2005; 95: 95-109.
 26. Westbrook MT Jr, West RA, McNeill RW. Simultaneous maxillary advancement and closure of bilateral alveolar clefts and oronasal fistulas. J Oral Maxillofac Surg 1983; 41: 257-60.
 27. Cheung LK, Samman N, Hui E, Tideman H. The 3-dimensional stability of maxillary osteotomies in cleft palate patients with residual alveolar clefts. Br J Oral Maxillofac Surg 1994; 32: 6-12.
 28. Erbe M, Stoelinga PJ, Leenen RJ. Long-term results of segmental repositioning of the maxilla in cleft palate patients without previously grafted alveolo-palatal clefts. J Craniomaxillofac Surg 1996; 24: 109-17.
 29. Garrison BT, Lapp TH, Bussard DA. The stability of Le Fort I maxillary osteotomies in patients with simultaneous alveolar cleft bone grafts. J Oral Maxillofac Surg 1987; 45: 761-6.
 30. Thongdee P, Samman N. Stability of maxillary surgical movement in unilateral cleft lip and palate with preceding alveolar bone grafting. Cleft Palate Craniofac J 2005; 42: 664-74.
 31. Posnick JC, Tompson B. Cleft-orthognathic surgery: complications and long-term results. Plast Reconstr Surg 1995; 96: 255-66.

การรักษาทันตกรรมจัดฟันร่วมกับการผ่าตัดกระดูกขากรรไกรพร้อมกับการปลูกกระดูกอัลวีโอลาร์ในผู้ป่วยปากแหว่งเพดานโหว่ ชนิดสมบูรณ์ข้างเดียว: รายงานผู้ป่วย

พูนศักดิ์ ภิสเอก, มนเทียร มโนสุตประสิทธิ์, ทศนีย์ วังศรีมงคล, สุทิน จินาพรรณธรรม, โอภาส วิวัฒน์วรกุล

เพื่อนำเสนอผู้ป่วยภาวะปากแหว่งเพดานโหว่หญิงไทยอายุ 22 ปี ซึ่งมีการสบฟันผิดปกติที่เกิดจากหลายสาเหตุ คือปัญหาเกี่ยวกับฟัน ความไม่ได้อัดส่วนกันของกระดูกโครงสร้างขากรรไกร และภาวะช่องโหว่ของกระดูกอัลวีโอลาร์ที่ยังไม่ได้รับการแก้ไข การรักษาผู้ป่วยรายนี้ คือ การจัดฟัน ร่วมกับการผ่าตัดแก้ไขความไม่ได้อัดส่วนกันของกระดูกโครงสร้างขากรรไกรและการผ่าตัดปลูกกระดูกอัลวีโอลาร์ในคราวเดียวกัน หลังการรักษาพบว่าผู้ป่วยมีความสวยงามของใบหน้าดีขึ้น มีการสบฟันที่ดี และมีความต่อเนื่องกันของกระดูกอัลวีโอลาร์ของขากรรไกรบน การรักษาวิธีนี้สามารถลดความเจ็บปวด การต้องนอนโรงพยาบาลครั้งที่สอง และลดค่าใช้จ่ายจากการผ่าตัดแก้ไขแบบสองครั้ง แต่อย่างไรก็ตามวิธีนี้เป็นเพียงทางเลือกหนึ่งของการรักษาผู้ป่วย ปากแหว่งเพดานโหว่ผู้ใหญ่ ที่จำเป็นต้องปลูกกระดูกอัลวีโอลาร์และผ่าตัดแก้ไขปัญหากระดูกโครงสร้าง