

Dentoalveolar Changes after Using Nasoalveolar Molding Device in Complete Unilateral Cleft Lip and Palate Patients

Raweewan Wongpetch DDS*, Montian Manosudprasit DDS, MDS, FRCDT*,
Waranuch Pitiphat DDS, MPH, MS, SD (Epidemiology), FRCDS (Dental Public Health)**,
Aggasit Manosudprasit DDS, MS, PhD*, Amornrut Manosudprasit DDS, MS*

* Department of Orthodontics, Faculty of Dentistry, Khon Kaen University, Khon Kaen, Thailand

** Department of Community Dentistry, Faculty of Dentistry, Khon Kaen University, Khon Kaen, Thailand

Objective: To determine the dimensional changes of alveolar bone cleft after using Khon Kaen University intra-oral contraction-screw plate together with nasal elevator molding and labial strapping prior to surgical lip repair.

Material and Method: Maxillary alveolar ridge models of 17 infants with complete unilateral cleft lip and palate between the year 2015 and 2017 were evaluated at the initiation of molding therapy (T1) and after therapy (T2) before cheiloplasty. Linear dimensions, including cleft width, anterior arch width, posterior arch width, arch length, midline deviation, and arch circumference were recorded using a digital vernier caliper. Data were analyzed with paired t-test.

Results: Maxillary alveolar ridge models were collected at the start of treatment. The average age was 24.5 days. The results showed that measurements at T1 were significantly decreased at T2 in the width of the alveolar cleft ($p < 0.001$), anterior arch width ($p = 0.002$), arch length ($p < 0.001$) and midline deviation ($p < 0.001$). On the other hand, arch circumference and posterior arch width showed a slight increase at T2.

Conclusion: The contraction-screw plate, supported by the labial strapping, was effective in reducing the severity of the alveolar cleft width and anterior portion of the arch. The arches were more symmetrical and centralized to the midline which would contribute to improved overall surgical correction and result in better repair of alveolar cleft.

Keywords: Unilateral cleft lip and palate, Nasoalveolar molding device

J Med Assoc Thai 2017; 100 (Suppl. 6): S117-S122

Full text. e-Journal: <http://www.jmatonline.com>

In Thailand, the incidence of cleft lip and palate is between 1.10 and 2.49 cases per 1,000 live births⁽¹⁾. Over 50% of affected patients live in the northeast region^(1,2).

Presurgical nasoalveolar molding (PNAM) is one approach to the correction of naso-labial deformity before primary surgical repair of the cleft during the first year of life. Previous studies have reported the effectiveness of PNAM in patients with unilateral cleft lip and palate (UCLP)⁽³⁻⁶⁾. Such techniques include putting surgical tapes with pressure on the labial segments, fitting of an intra-oral obturator to guide the alveolar cleft segments into the desired position and application of nasoalveolar molding.

Treatment for the complete UCLP infants at the Department of Orthodontics, Khon Kaen University (KKU) uses a modification of Grayson et al.'s treatment

protocol and presurgical nasoalveolar molding technique⁽⁴⁾ with the Khon Kaen University presurgical nasoalveolar molding (KKU-PNAM). The KKU-PNAM method⁽⁷⁾ consists of three components: (1) extra-oral forehead supported nostril elevator molding; (2) extra-oral strapping which is applied to approximate lip segments to reduce alveolar cleft width; and (3) an active alveolar molding plate with traction screw, which is used to reduce the size of the alveolar cleft.

The effectiveness of this KKU-PNAM device on treatment of unilateral complete cleft lip and palate has never been evaluated. Therefore, the purpose of this study was to determine the changes of alveolar bone cleft and arch form using KKU-PNAM prior to surgical lip repair.

Material and Method

This study collected all the data required from alveolar ridge casts of UCLP patients who received treatment based on the protocols of KKU Cleft Center between January 2015 and January 2017 and were approved by the Khon Kaen University Ethics

Correspondence to:

Manosudprasit M, Department of Orthodontics, Faculty of Dentistry, Khon Kaen University, Khon Kaen 40002, Thailand.
Phone & Fax: +66-43-202863
E-mail: monman@kku.ac.th

Committee (HE602061).

Maxillary alveolar ridge models of 17 infants (10 females and 7 males) with complete unilateral cleft lip and palate were evaluated at the initiation of molding therapy (T1, Fig. 1A) and after therapy (T2, Fig. 1B) before cheiloplasty.

Definitions of landmarks and measurements on the alveolar ridge casts are shown in Table 1. The conventionally used landmarks were lightly marked on the casts with a 0.5-mm pencil to identify all landmarks (Fig. 2A, 2B) by one investigator (RW).

Distances were measured to the nearest 0.01 mm, using a digital vernier caliper (Hummer 573-121, NTD12-15, 0.01-150 mm.) as seen in Table 2.

Reproducibility of the measurements was determined from all recordings in 17 UCLP patients. Each measurement was examined twice with 1-month interval. Intraclass correlation coefficients (ICC) were calculated for duplicate measurements. The ICCs were greater than 0.89 for all measurements, indicating excellent intra-observer reliability.

Data were summarized as means and 95% confidence intervals. Differences in the measurements before and after treatment were normally distributed

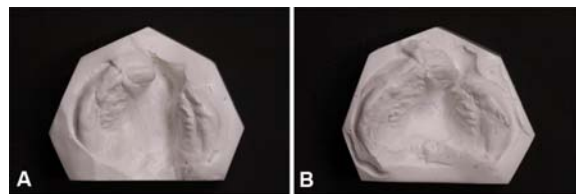


Fig. 1 A pair of alveolar ridge models used in this study. (A) Before molding therapy, T1; (B) After molding therapy and before cheiloplasty, T2.

and therefore analyzed using paired t-test. The p -values <0.05 were considered statistically significant. All statistical analyzes were performed using SPSS version 19 statistical software (SPSS, Chicago, IL, USA).

Results

The UCLP patients consisted of 10 females and 7 males. The average age of the patients at the start of treatment was 24.5 days (standard deviation, $SD = 23.5$). The average treatment time was 103.3 days ($SD = 34.6$), with a range between 65 and 182 days.

When comparing the measurements at two time points (Table 3), there was a highly significant decrease in the width of alveolar cleft ($p < 0.001$), anterior arch width ($p = 0.002$), arch length ($p < 0.001$), and midline deviation ($p < 0.001$). A marginally significant decrease in arch circumference was observed at T2. On the other hand, posterior arch width showed only a slight increase at T2.

Discussion

The KCU-PNAM treatment has three

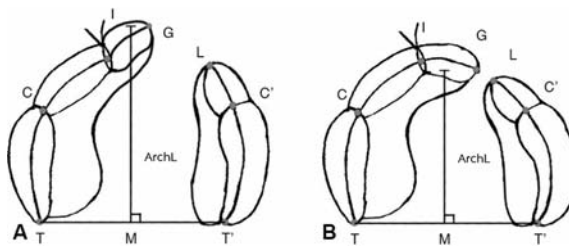


Fig. 2 Landmark identification and linear measurements used in this present study⁽⁵⁾. (A) Pretreatment alveolar ridge cast, T1; (B) Posttreatment alveolar ridge cast, T2.

Table 1. Definitions of landmarks and measurements on the alveolar ridge casts

Reference points	Abbreviation	Definition
Incisor point	I	Point of intersection between the alveolar ridge and groove of the median labial frenum
Mid point	M	Midpoint of T-T'
Cleft edge point	G	Midpoint of the margin of the larger segment
Cleft edge point	L	Midpoint of the margin of the smaller segment
Canine point	C and C'	Point of intersection between the alveolar ridge and groove of the lateral buccal frenum in greater segment on right and left sides of model If the infant does not have any buccal frenum at the area of deciduous canine, consider the crest of the alveolar bridge in the deciduous canine region as the position of the canine point.
Tuberosity point	T and T'	Tuberosity point, junction of the alveolar ridge with the outline of the tuberosity in greater segment on right and left sides of model

components. Treatment begins with the nasal elevator⁽⁸⁻¹⁰⁾. Lip strapping is applied and within two weeks a third component, an active intra-oral plate, is introduced to reduce the alveolar cleft width preparatory to primary surgery for closure of the anterior clefts.

Comparing the present study with previous reports

The screw-plate significantly reduced the cleft width, anterior arch width and midline deviation as expected. The posterior arch width and arch circumference in the pretreatment group and the posttreatment group were slightly increased.

Reduction of the cleft width and good alignment of the palatal segments lessens the distance between the greater and lesser segments. The contour of the dental arch was normalized without collapsing the dental alveolar segments. Therapy modified the affected arch by advancing the segment medially as

well as anteriorly⁽¹¹⁾.

The alveolar ridge cast measurement revealed a significant reduction of the anterior alveolar cleft width in all the cases. There was a slight decrease in the arch width of both greater and lesser segments. The posterior arch widths were slightly increased. It seems that the appliance did not adversely affect the transverse growth of the maxilla in the posterior region and thus the therapy mainly acted through redirection of the alveolar segments and not by restricting its growth. The potential factor for changes in arch circumference and posterior arch width could be as a result of the expected infantile growth spurt during the early infancy period.

The changes in the anterior region of alveolus could be associated with the following:

1) Lip strapping is used to approximate greater and lesser lip and alveolus segments as soon as possible after birth.

2) The active alveolar molding plate was constructed from self-cured hard acrylic on a setup model combined with a traction screw, followed by sequential plate changes. Moreover, these would foster changes by removing the effects of tongue action on the intra-oral cleft opening and allowing free growth of the palatal shelves⁽¹²⁾.

The rehabilitation of cleft lip and palate patients continues to be a challenge for all the cleft centers around the world. The proposal to treat these patients is to restore the abnormality close to normal as possible. So there are assorted treatment modalities for the management of presurgical orthopedic for

Table 2. Definition of linear measurements⁽⁵⁾

Linear variables	Description
Width dimension	
G-L	Width of the cleft
C-C'	Anterior arch widths
T-T'	Posterior arch widths
Length dimension	
Arch length	G perpendicular to T-T' line
Midline deviation	Perpendicular distance from I point to line from M point
Arch circumference	Sum of distance T-C-I-G-L-C'-T'

Table 3. Comparison of the measurements before and after treatment with Khon Kaen University presurgical nasoalveolar molding (KKU-PNAM)

Parameter	Before (T1)	After (T2)	Paired Differences				t	p-value
			Mean	S.D	95% Confidence Interval			
					Lower	Upper		
Cleft width	9.89	2.74	7.18	2.91	5.69	8.68	10.19	<0.001*
Anterior arch width	29.89	27.11	2.60	2.98	1.06	4.13	3.60	0.002*
Posterior arch width	33.81	34.94	-1.16	3.94	-3.18	0.87	-1.21	0.244
Arch length	22.88	20.36	2.32	1.63	1.48	3.16	5.86	<0.001*
Midline deviation	6.00	2.64	3.28	1.60	2.46	4.10	8.50	<0.001*
Arch circumference	64.51	61.66	2.70	5.28	-0.01	5.42	2.11	0.051

* Statistically significant

infants with cleft lip and palate with attempts to obtain aesthetic results and aid in reducing the extent of distortion, deviation, and displacement of the affected structures⁽¹³⁾.

Current status of presurgical nasoalveolar molding treatment has been developed among multidisciplinary cleft teams. Advantages are claimed for PNAM in the benefits for reducing the initial deformity before surgery such as decreasing the cleft width^(6,8,13-16); numerous cleft teams use the Grayson's PNAM procedure or minor variations of it.

Positive effects such as facilitating surgery and improving outcomes in general and additional psychological support for parents are also claimed in the literature. On the other hand, negative effects are also noted. For example, this treatment is a complex and expensive therapy and is not evidence-based. In addition, parents are obliged to travel frequently for treatment during the first year of the infant's life and put up with the burden of compliance. Moreover, there remains the possibility that scar tissue in the alveolar ridge can potentially interfere with maxillary displacement and secondary fill-in growth at the growth sites.

It has been shown in a randomized controlled clinical trial (DutchCleft)⁽¹⁷⁾ that presurgical infant orthopedics, which also could imply to PNAM, has only a temporary effect on maxillary arch dimension and does not last beyond surgical soft palate closure. None of the PNAM studies that have been located specifically mentioned the contribution that natural growth must make to the measured changes.

Randomized controlled clinical trials (RCTs) provide the highest level of evidence because they are based on comparisons of long-term outcomes with different approaches to presurgical treatment of CLP^(18,19). Grayson and Garfinkle⁽²⁰⁾ have realized that all of the reports of NAM lack acceptable evidence of positive benefits since there have been no prospective randomized clinical trials (PRCT) of the use of NAM compared with other approaches in managing nasal deformities of babies with complete UCLP. They used the example of Bongaarts et al. (Dutchcleft) to report of a presurgical orthopedic treatment (PSOT) that found no benefit of presurgical infant orthopedics (*e.g.* Hotz method).

Sackett⁽²¹⁾ stated that the lack of objective evidence from randomized clinical trials in orthodontics is an underlying cause of many orthodontics controversies.

".....We cannot confidently infer anything

about efficacy through the study of patients outside of a trial. We can, however, in leading us to an eventual clinical trial, agree on a level of evidence and a 'trail to next-best evidence' that will more reliably inform our decisions about treatment options for our patients".

Chang et al.⁽²²⁾ reported a rare example of an attempt at what could be regarded as a prospective controlled clinical trial that included the use of PNAM. This study analyzed treatment outcomes comparing NAM with other treatment approaches for primary nose-lip repair. They separated treatment regimes for four groups of 16 to 23 subjects up to 5 years of age into: (1) primary rhinoplasty alone; (2) nasoalveolar molding alone (no rhinoplasty); (3) nasoalveolar molding with primary rhinoplasty; and (4) nasoalveolar molding with primary rhinoplasty plus overcorrection. The results showed that group IV had the best overall results. However, it must be noted that this study could be best regarded as only an interim RCT report since it had only been carried through to the subjects' age of 5 years.

Limitations of the present study

This present study was restricted to assessing only the dimensions of arch width and length changes before primary surgery, but not with any follow-up such as to check for any post-surgical relapse. The rural center where the unit is catered for a large number of underprivileged people and many of them have reported late for treatment for a variety of reasons, ranging from socioeconomic issues, lack of awareness, poor referral systems, and lack of cooperation from patients' parents. The needs for parental cooperation in order to obtain successful treatment outcomes were stressed in the initial visit. Further studies for long-term benefits of the KKU-PNAM treatment protocols are needed, like Grayson's PNAM, there is no evidence of the level of benefit since randomized clinical trials starting from infancy have yet to be planned.

Conclusion

The present study was conducted on maxillary alveolar ridge models with complete UCLP to evaluate changes in maxillary alveolar morphology after the KKU-PNAM. The contraction-screw plate is effective in reducing the severity of the alveolar cleft width and anterior portion of the arch. The arches are more symmetrical and centralized to the midline which would facilitate overall surgical correction leading better surgical outcomes.

What is already known on this topic?

There have been many previous studies⁽³⁻⁶⁾ reported on the effectiveness of presurgical nasoalveolar molding in patients with UCLP. The benefits of PNAM are claimed for reducing the initial deformity before surgery such as decreasing the cleft width^(6,8,13-16); numerous cleft teams use the Grayson's PNAM procedure or minor variations of it.

What this study adds?

The Department of Orthodontics, Khon Kaen University uses a modification of Grayson et al. treatment protocol and presurgical nasoalveolar molding technique⁽⁴⁾ with the KCU-PNAM. Among various techniques to reduce the alveolar gap, the department preferred extra-oral strapping at the first two weeks to reduce some alveolar cleft and later to close the remaining alveolar cleft by active alveolar molding plate with contraction-screw. Benefits of the KCU-PNAM devices are to control each organ separately with 3 devices and perform extra-oral strapping as early as possible. The results of the present study is necessary for the development of a modified device to reduce the severity of initial cleft deformities in patients and provide a basic knowledge of further studies of the device.

Acknowledgements

The authors would like to express their sincere thanks to "The Center of Cleft Lip-Cleft Palate and Craniofacial Deformities, Khon Kaen University under Tawanchai Royal Grant Project" for publication support.

Potential conflicts of interest

None.

References

1. Chuangsuwanich A, Aojanepong C, Muangsombut S, Tongpiew P. Epidemiology of cleft lip and palate in Thailand. *Ann Plast Surg* 1998; 41: 7-10.
2. Pradubwong S, Lekbunyasins O, Chantachum V, Udomtanassup S, Simmalee K, Chowchuen B. Application of Geographic Information System (GIS) for management of cleft lip-palate care at the Tawanchai Cleft Center. *J Med Assoc Thai* 2010; 93 (Suppl 4): S58-62.
3. Grayson BH, Cutting CB. Presurgical nasoalveolar orthopedic molding in primary correction of the nose, lip, and alveolus of infants born with unilateral and bilateral clefts. *Cleft Palate Craniofac J* 2001; 38: 193-8.
4. Grayson BH, Maull D. Nasoalveolar molding for infants born with clefts of the lip, alveolus, and palate. *Clin Plast Surg* 2004; 31: 149-58.
5. Sabarinath VP, Thombare P, Hazarey PV, Radhakrishnan V, Agrekar S. Changes in maxillary alveolar morphology with nasoalveolar molding. *J Clin Pediatr Dent* 2010; 35: 207-12.
6. Shetty B, Puthiyaveedu S, Muddaiah S, Somaiah S, Vijayanand K, Jacob J. Evaluation of pre- and post-treatment changes in the alveolus of infants with cleft lip and palate using nasoalveolar molding. *APOS Trends in Orthodontics* 2013; 3: 110-5.
7. Manosudprasit M, Chongcharueyskul P, Wangsrimonkol T, Pisek P. Presurgical nasoalveolar molding techniques for a complete unilateral cleft lip and palate infant: A case report. *J Med Assoc Thai* 2015; 98 (Suppl 7): S234-42.
8. Monasterio L, Ford A, Gutierrez C, Tastets ME, Garcia J. Comparative study of nasoalveolar molding methods: nasal elevator plus DynaCleft(R) versus NAM-Grayson in patients with complete unilateral cleft lip and palate. *Cleft Palate Craniofac J* 2013; 50: 548-54.
9. Berggren A, Abdiu A, Marcusson A, Paulin G. The nasal alar elevator: an effective tool in the presurgical treatment of infants born with cleft lip. *Plast Reconstr Surg* 2005; 115: 1785-7.
10. Abdiu A, Ohannessian P, Berggren A. The nasal alar elevator: a new device that may reduce the need for primary operation of the nose in patients with cleft lip. *Scand J Plast Reconstr Surg Hand Surg* 2009; 43: 71-4.
11. Ezzat CF, Chavarria C, Teichgraber JF, Chen JW, Stratmann RG, Gateno J, et al. Presurgical nasoalveolar molding therapy for the treatment of unilateral cleft lip and palate: a preliminary study. *Cleft Palate Craniofac J* 2007; 44: 8-12.
12. Ball JV, DiBiase DD, Sommerlad BC. Transverse maxillary arch changes with the use of preoperative orthopedics in unilateral cleft palate infants. *Cleft Palate Craniofac J* 1995; 32: 483-8.
13. Radhakrishnan V, Sabarinath VP, Thombare P, Hazarey PV, Bonde R, Sheorain A. Presurgical nasoalveolar molding assisted primary reconstruction in complete unilateral cleft lip palate infants. *J Clin Pediatr Dent* 2010; 34: 267-74.
14. Huddart AG. Presurgical changes in unilateral cleft palate subjects. *Cleft Palate J* 1979; 16: 147-57.
15. Baek SH, Son WS. Difference in alveolar molding

- effect and growth in the cleft segments: 3-dimensional analysis of unilateral cleft lip and palate patients. *Oral Surg Oral Med Oral Pathol Oral Radiol Endod* 2006; 102: 160-8.
16. Shetty V, Vyas HJ, Sharma SM, Sailer HF. A comparison of results using nasoalveolar moulding in cleft infants treated within 1 month of life versus those treated after this period: development of a new protocol. *Int J Oral Maxillofac Surg* 2012; 41: 28-36.
 17. Prah C, Kuijpers-Jagtman AM, van't Hof MA, Prah-Andersen B. A randomised prospective clinical trial into the effect of infant orthopaedics on maxillary arch dimensions in unilateral cleft lip and palate (Dutchcleft). *Eur J Oral Sci* 2001; 109: 297-305.
 18. Hathaway RR, Long RE Jr. Early cleft management: in search of evidence. *Am J Orthod Dentofacial Orthop* 2014; 145: 135-41.
 19. Burns PB, Rohrich RJ, Chung KC. The levels of evidence and their role in evidence-based medicine. *Plast Reconstr Surg* 2011; 128: 305-10.
 20. Grayson BH, Garfinkle JS. Early cleft management: the case for nasoalveolar molding. *Am J Orthod Dentofacial Orthop* 2014; 145: 134-42.
 21. Sackett DL. *Orthodontic treatment: outcome and effectiveness. Monograph 30.* Ann Arbor, MI: Craniofacial Growth Series Center for Human Growth and Development, University of Michigan; 1995.
 22. Chang CS, Por YC, Liou EJ, Chang CJ, Chen PK, Noordhoff MS. Long-term comparison of four techniques for obtaining nasal symmetry in unilateral complete cleft lip patients: a single surgeon's experience. *Plast Reconstr Surg* 2010; 126: 1276-84.

การเปลี่ยนแปลงของกระดูกรองรับฟันหลังจากใช้เครื่องมือปรับแต่งจมูกและกระดูกรองรับฟันในผู้ป่วยปากแหว่งเพดานโหว่ สมบูรณ์ด้านเดียว

รวีวรรณ วงษ์เพชร, มนเทียร มโนสุตประสิทธิ์, วราวุธ ปิติพัฒน์, เอกสิทธิ์ มโนสุตประสิทธิ์, อมรรัตน์ มโนสุตประสิทธิ์

วัตถุประสงค์: เพื่อประเมินการเปลี่ยนแปลงของรอยแยกของกระดูกรองรับฟัน และรูปร่างของขากรรไกรหลังจากใช้แผ่นเพดานเทียมที่มีสกรูช่วยเคลื่อนกระดูกรองรับฟันให้ชิดกัน เครื่องมือปรับรูปร่างของจมูก ร่วมกับใช้แถบคาคริมฟีปากของมหาวิทยาลัยขอนแก่น ก่อนการผ่าตัดเย็บริมฝีปาก
วัสดุและวิธีการ: ทำการประเมินแบบพิมพ์สันเหงือกขากรรไกรบนของผู้ป่วยทารกที่มีปากแหว่งเพดานโหว่สมบูรณ์ด้านเดียวระหว่าง พ.ศ. 2558 ถึง 2560 จำนวน 17 คน ซึ่งได้รับการรักษาโดยเครื่องมือข้างต้น ทำการประเมินก่อนการรักษา (T1) และหลังการรักษา (T2) ก่อนการผ่าตัดเย็บริมฝีปาก โดยวัดระยะมิติเชิงเส้น ได้แก่ ช่องกว้างของรอยแยกสันเหงือก ระยะความกว้างของขากรรไกรส่วนหน้า ระยะความกว้างของขากรรไกรส่วนหลัง ความยาวส่วนโค้งขากรรไกร ระยะการเบี่ยงเบนของจุดกึ่งกลางของสันเหงือก และระยะโดยรอบของส่วนโค้งขากรรไกร ถูกวัดโดยใช้เวอร์เนียร์คาลิเปอร์แบบดิจิทัล ข้อมูลทั้งหมดถูกวิเคราะห์โดยสถิติการทดสอบความแตกต่างของค่ากลางของสองประชากรไม่อิสระ

ผลการศึกษา: แบบพิมพ์สันเหงือกขากรรไกรบนที่เก็บข้อมูลก่อนการรักษาของผู้ป่วยทารกอายุเฉลี่ย 24.5 วัน พบว่าค่าการวัด T1 มีการลดลงอย่างมีนัยสำคัญเมื่อเปรียบเทียบกับ T2 ในส่วนช่องกว้างของรอยแยกสันเหงือก ($p < 0.001$) ระยะความกว้างของขากรรไกรส่วนหน้า ($p = 0.002$) ความยาวส่วนโค้งของขากรรไกร ($p < 0.001$) ระยะการเบี่ยงเบนของจุดกึ่งกลางของสันเหงือก ($p < 0.001$) ส่วนระยะความกว้างของขากรรไกรส่วนหลัง และระยะโดยรอบของส่วนโค้งขากรรไกร พบมีการเปลี่ยนแปลงเพิ่มขึ้นเล็กน้อยหลังการรักษา

สรุป: แผ่นเพดานเทียมที่มีสกรูช่วยเคลื่อนกระดูกรองรับฟันให้ชิดกัน มีประสิทธิภาพในการลดระดับความรุนแรงของช่องกว้างของรอยแยกสันเหงือกและบริเวณความกว้างของส่วนโค้งขากรรไกรส่วนหน้า ทำให้ส่วนโค้งของขากรรไกรมีลักษณะสมมาตรมากขึ้น และจุดกึ่งกลางของสันเหงือกเข้าสู่จุดกึ่งกลางมากขึ้นซึ่งช่วยในการผ่าตัดเย็บริมฝีปากและให้ผลการรักษาที่ดีขึ้น