

Cardiovascular Malformations in Patients with Treacher Collins Syndrome: A Systematic Review

Manat Panamonta MD¹, Arnkisa Chaikitpinyo MD¹, Yuttapong Wongswadiwat MD¹,
Paradorn Chan-on MD¹, Ouyporn Panamonta MD¹, Khunton Wichajarn MD¹

¹ Department of Pediatrics, Faculty of Medicine, Khon Kaen University, Khon Kaen, Thailand

Background: Cardiovascular malformation is an uncommon extra-craniofacial presentation in a patient with Treacher Collins syndrome [TCS], however, a systematic review of this manifestation is lacking.

Objective: To systematically review of prevalence and type of cardiovascular malformations in patients with TCS.

Materials and Methods: A systematic literature search was conducted through PubMed, Google Scholar, Cochrane central data bases, and OMIM using the medical subject heading “Treacher Collins syndrome” for articles published between 1996 and March 2018.

Results: Of the 15 studies included, there were 159 patients who had a clinical diagnosis of TCS and 144 (91%) of these patients had documented gene mutations [i.e., *TCOF1* (114 patients), *POLRIC* (3 patients), or *POLRID* (27 patients)]. Of the 144 patients who had been documented gene mutations, eight (6%) patients had cardiovascular malformations. All 8 patients with cardiovascular malformations had only the *TCOF1* gene mutations. The type of cardiovascular malformations were atrial septal defect [ASD] (5 cases), patent ductus arteriosus [PDA] (2 cases) and ASD + PDA (1 case).

Conclusion: The prevalence of cardiovascular malformation significantly increases in patients with TCS compared with the general population. Cardiovascular malformation found in a patient with TCS is likely to present as a simple lesion.

Keywords: Treacher Collins syndrome, Treacher Collins-Franceschetti syndrome, Cardiovascular malformations, Congenital heart diseases, Prevalence, Type, *TCOF1*, *POLRIC*, *POLRID*, Gene

J Med Assoc Thai 2018; 101 (Suppl. 5): S221-S226

Full text. e-Journal: <http://www.jmatonline.com>

Treacher Collins syndrome [TCS] [Online Mendelian Inheritance in Man (OMIM): TCS-1: 154500, TCS-2: 613717, TCS-3: 248390], sometimes known as Treacher Collins-Franceschetti syndrome, is a craniofacial malformation syndrome resulting from developmental disorders of the first and second pharyngeal arches⁽¹⁾, and it is the most common mandibulofacial dysostosis, occurring in ~1 in 50,000 live births in the general population^(1,2). The syndrome is named after Dr. Edward Treacher Collins⁽³⁾ and Dr. Adolphe Franceschetti⁽⁴⁾ who first described the syndrome. Its major craniofacial abnormalities include

downward slanting of the palpebral fissures (eyelids) (anti-mongoloid slant eyes), malar and mandibular hypoplasia, coloboma (notch) of the lower eyelid, microtia (small ear) and conductive hearing loss⁽⁵⁻⁷⁾. Associated malformations frequently include dental abnormalities, projection of the scalp hair into the lateral cheek area, and cleft palate^(1,5).

Previously, diagnosis of TCS was based on the typical craniofacial anomalies^(3,4). Recently, mutation abnormalities of three genes (*TCOF1* [cytogenetic location: 5q32-q33], *POLRIC* [cytogenetic location: 6p21.1], and *POLRID* [cytogenetic location: 13q12.2]) have been identified in the majority of patients with craniofacial features compatible with TCS⁽⁶⁻¹⁰⁾. In the case of *TCOF1* mutation [TCS-1], the mode of inheritance is autosomal dominant, while for the *POLRIC* mutation (TCS-3), it is autosomal

Correspondence to:

Panamonta M, Department of Pediatrics, Faculty of Medicine, Khon Kaen University, Khon Kaen 40002, Thailand.

Phone: +66-81-7683538, **Fax:** +66-43-348382

E-mail: manat@kku.ac.th

How to cite this article: Panamonta M, Chaikitpinyo A, Wongswadiwat Y, Chan-on P, Panamonta O, Wichajarn K. Cardiovascular Malformations in Patients with Treacher Collins syndrome: A Systematic Review. J Med Assoc Thai 2018;101;Suppl. 5: S221-S226.

recessive⁽⁶⁻⁹⁾. Medially, the *POLR1D* mutation (TCS-2) can be either autosomal dominant or autosomal recessive⁽⁶⁻⁹⁾. The *TCOF1*, *POLR1C*, and *POLR1D* genes are responsible for ribosome biogenesis, which is a general mechanism for cell proliferation and cell growth⁽⁷⁻¹⁰⁾. Mutations of these genes result in defects to RNA biogenesis and abnormal ribosome functions^(1,6-9). The spectrum of clinical presentations of TCS can be accurately determined with a molecular assessment as a patient with an uncommon presentation can be included in the spectrum of the syndrome if they have *TCOF1*, *POLR1C*, and/or *POLR1D* gene mutations⁽⁶⁻¹⁰⁾.

Although craniofacial presentations is a major concern for this syndrome, cardiovascular abnormalities have rarely been reported^(5,8,11-27). Since there has been no previous systematic review of cardiovascular involvement of the syndrome, the authors of the current study summarized the respective frequencies and types of cardiovascular malformations in cohorts of patients with genetically documented TCS in order to improve awareness of cardiovascular malformations in patients with the syndrome.

Materials and Methods

Data sources

A systematic literature search was conducted using electronic databases (viz., PubMed, Google Scholar, Cochrane central data bases, and OMIM), using the medical subject heading “Treacher Collins syndrome” for articles published between January 1996 and March 2018. The eligible articles in all languages were included and screened. The titles and abstracts of the relevant articles were assessed independently by the two authors (MP and OP) to identify potential articles for which full text publications were retrieved. Reference lists of included articles were examined for additional relevant articles that may have been missed in the search.

Definitions

Cardiovascular malformation was defined as a defect in the structure and function of the heart or great vessel presented at birth.

Treacher Collins syndrome was defined as typical clinical findings, including downward slanting of the palpebral fissures (eyelids), (anti-mongoloid slant eyes), malar and mandibular hypoplasia, coloboma (notch) of the lower eyelid, microtia (small ear), and conductive hearing loss. In these cases, a molecular genetic assessment was used

to confirm the diagnosis of TCS (i.e., a mutation in the *TCOF1*, *POLR1C* and *POLR1D* genes).

Study selection

All published articles and case reports of patients with TCS who had a molecular diagnosis of the *TCOF1*, *POLR1C* and *POLR1D* genes were considered for inclusion. When a study was eligible for inclusion, the authors (MP and OP) independently verified the frequencies and types of cardiovascular malformations or congenital heart diseases to check for accuracy. Any reports that presented only clinical features without gene confirmations data were excluded. Disagreements were resolved by consensus.

Data extraction

The data extracted from each research article included (a) total number of patients with clinical diagnosis of TCS, (b) number of patients with gene mutation identified, (c) number of cases with cardiovascular malformations, and (d) types of cardiovascular malformations.

Quality assessment

Studies were assessed on completeness of data. The molecular assessment for each study was determined as patients with cardiovascular malformations were included within the spectrum of the syndrome if gene mutations were confirmed.

Statistical analyses

The frequencies of cardiovascular malformations in TCS were reported as a percentage.

Results

The database search revealed 14,775 relevant articles. After applying the study selection criteria, 14,760 articles were excluded, so only 15 articles met the selection criteria and were extensively reviewed. After the critical review, 1 article was excluded due to incomplete data. After reference checking of the included 14 articles, an additional study was found. This additional study was not initially retrieved because it had not been indexed in the searched databases. Ultimately, 15 articles were eligible for inclusion in this systematic review (Figure 1).

From among the 15 studies included, there were 159 patients who had a clinical diagnosis of TCS and 144 (91%) of these patients had documented gene mutations [i.e., *TCOF1* (114 patients), *POLR1C* (3 patients), or *POLR1D* (27 patients)]. Of the 144

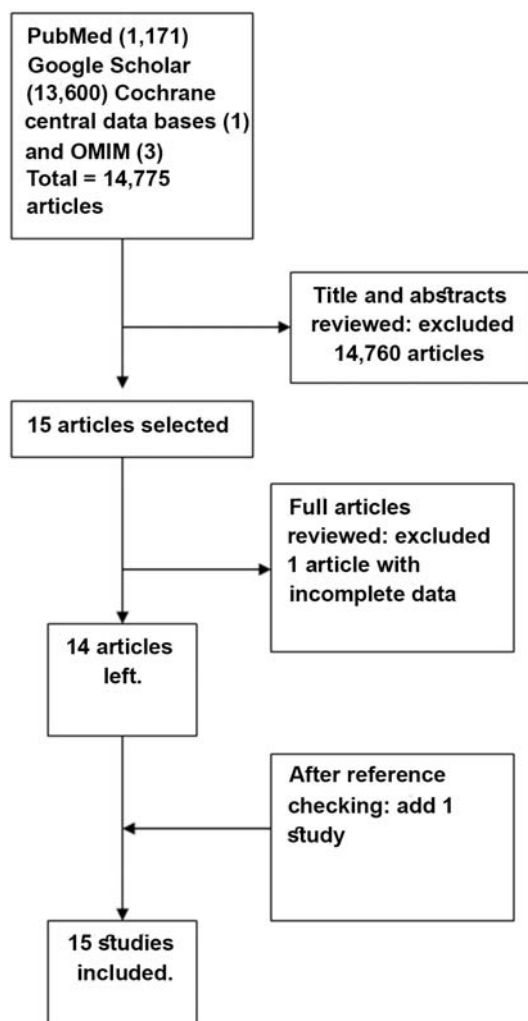


Figure 1. Flow diagram of the articles included into this systematic review.

patients who had documented gene mutations, eight (6%) patients had cardiovascular malformations (Table 1). All 8 patients with cardiovascular malformations had only the *TCOF1* gene mutation. The types of cardiovascular malformations included atrial septal defect [ASD] (5 cases), patent ductus arteriosus [PDA] (2 cases), and ASD + PDA (1 case) (Table 1).

Discussion

In this systematic review, the pooled average frequency of cardiovascular malformations was found in 6% of patients with TCS whose diagnoses were confirmed by molecular gene studies. In the general population, it is estimated that ~1% of live birth infants have congenital cardiovascular malformations⁽²⁸⁻³⁰⁾. The

significance of this finding is that patients with TCS have higher prevalence of cardiovascular malformations than the general population. Although cardiovascular malformation is an uncommon presentation in a patient with TCS, this malformation should be carefully evaluated in each patient with a confirmed diagnosis of TCS. Physicians providing care to patients with TCS should, thus, be aware of the potential for cardiovascular malformation association of this syndrome.

The type of cardiac malformations in genetically-unconfirmed case reports of TCS has been documented to be atrial and ventricular septal defects, patent ductus arteriosus, coarctation of the aorta, and sinus of Valsalva aneurysm⁽²³⁻²⁷⁾ (Table 2). The present review including gene-mutation confirmed TCS had similar findings regarding the types of cardiovascular malformations (i.e., atrial septal defect and patent ductus arteriosus). Cardiovascular malformation in a patient with TCS is most likely to present as a simple lesion that is not difficult to manage during patient care or craniofacial surgery.

TCS results from mutations in the *TCOF1*, *POLRIC* or *POLRID* genes, resulting in abnormal craniofacial developments. According to molecular studies of the 8 patients with cardiovascular malformations, 7 had frame shift mutations and 1 had a non-sense mutation of *TCOF1* gene (Table 1). *TCOF1* gene is responsible for encoding treacle protein which involved in mRNA formation in neural crest cells during embryogenesis^(7,24). Abnormalities in this pathway are hypothesized to lead to early neural crest cell apoptosis and neural crest cell depletion in pharyngeal arches 1 and 2^(1,7). These events result in cartilage, bone, and connective tissue hypoplasia, which leads to the characteristic craniofacial abnormalities associated with TCS and is also involved in the etiology of cardiovascular malformation⁽²³⁻²⁶⁾.

With respect to pathogenesis, the most important finding may be that there are relatively fewer frequencies of cardiovascular malformation found in TCS in comparison with other syndromes with abnormal development of neural crest cells (i.e., the 22q11.2 deletion syndrome or Goldenhar syndrome)^(28,29). A better understanding of the pathogenesis of the syndrome could help identify the etiologies of the various cardiovascular malformations involved. Although some TCS patients may show apparent cardiovascular malformations or congenital heart diseases, such presentations are sometimes overlooked and under-reported.

Table 1. Frequency and type of cardiovascular malformations in 144 patients with gene-mutation confirmed Treacher Collins syndrome.

Authors/Years	Number of patients with gene mutation identified/Total number of patients with clinical diagnosis of TCS	Number of cases with cardiovascular malformations (N)		Number of cases with cardiovascular malformations (N) with cardiovascular malformations (N)/ Total numbers of patients with gene-mutation confirmed TCS (%)	Types of cardiovascular malformations (N)
		N/Number of patients with <i>TCOF1</i> gene mutation	N/Number of patients with <i>POLRIC</i> gene mutation		
Giabicani et al ⁽¹⁾ /2017	1/1	0/1	ND	0/1 (0)	NA
Vincent et al ^{(6)*} /2016	65/70	7 ^a /60	0/5	7 ^a /65 (11)	ASD (4), PDA (2), ASD with hypertrophic cardiomyopathy (1)
Hao et al ⁽¹²⁾ /2016	3/3	0/3	ND	0/3 (0)	NA
Wang et al ⁽¹³⁾ /2014	3/3	0/3	ND	0/3 (0)	NA
Schaefer et al ⁽⁹⁾ /2014	2/2	0/0	0/2	0/2 (0)	NA
Zhang et al ⁽⁴⁾ /2013	2/2	0/2	ND	0/2 (0)	NA
Bauer et al ⁽¹⁵⁾ /2013	2/2	0/2	ND	0/2 (0)	NA
Ulusal et al ⁽¹⁶⁾ /2013	1/1	0/1	ND	0/1 (0)	NA
Marszalek-Kruk et al ⁽¹⁷⁾ /2012	2/2	0/2	ND	0/2 (0)	NA
Dauwarse et al ^{(8)*} /2011	23/23	ND	0/3	0/23 (0)	NA
Li et al ⁽¹⁸⁾ /2009	1/1	1 ^b /1	ND	1 ^b /1 (100)	ASD + PDA + mesocardia (1)
Writzl et al ⁽¹⁹⁾ /2008	1/1	0/1	ND	0/1 (0)	NA
Horiuchi et al ⁽²⁰⁾ /2005	9/11	0/9	ND	0/9 (0)	NA
Teber et al ^{(21)*} /2004	28/36	0/28 ^c	ND	0/28 ^c (0)	NA
Horiuchi et al ⁽²²⁾ /2004	1/1	0/1	ND	0/1 (0)	NA
Total	144/159	8 ^d /114	0/3	8 ^d /144 (6)	ASD (4), PDA (2), ASD with hypertrophic cardiomyopathy (1), ASD + PDA + mesocardia (1)

TCS = Treacher Collins syndrome; N = number of cases with cardiovascular malformations; ND = not determined; NA = not available; ASD = atrial septal defect, secundum type; PDA = patent ductus arteriosus

^a Among the seven patients with cardiovascular malformations, six had a frame shift mutation and one had a non-sense mutation of the *TCOF1* gene.

^b A patient with a cardiovascular malformation had a frame shift mutation of the *TCOF1* gene.

^c The sister of a patient's father had clinical features of TCS (not molecular proved) with cardiac insufficiency.

^d Overall the eight patients with cardiovascular malformations, seven had a frame shift mutation and one had a non-sense mutation of *TCOF1* gene.

^e Prospective studies

Table 2. Cardiovascular malformations associated with genetically unconfirmed Treacher Collins syndrome

Authors/Years	Types of cardiovascular malformations (numbers)
Dinlen et al ⁽²³⁾ /2014	ASD + VSD + PA + persistence of LSVC (1) ^{ab}
Dobrilovic et al ⁽²⁴⁾ /2013	Sinus of Valsalva aneurysm + AR (1)
Albarran et al ⁽²⁵⁾ /2013	Sinus of Valsalva aneurysm (1)
Tsitouridis et al ⁽²⁶⁾ /2007	ASD + VSD + Coarctation of aorta (1)
Gottsegen et al ⁽²⁷⁾ /1956	VSD (1)

ASD = atrial septal defect, secundum type; VSD = ventricular septal defect; PA = pulmonary valve atresia; LSVC = left superior vena cava; AR= aortic regurgitation.

^a Modified Blalock-Taussig shunt at 6th day of life and sudden cardiac arrest at 30th day of life.

^b It was not clear whether cardiovascular malformations were parts of the TSC or caused by paroxetine exposure

Limitations of this study lie in its methodology. The available studies were mostly retrospective case series and case reports with few patients and sometimes a lack of screening for extra-craniofacial features (e.g., cardiovascular malformations). The methodology used to diagnose cardiovascular malformation or congenital heart disease is not always presented; nevertheless, the current literature review provides comprehensive data suggesting that cardiovascular malformation is occurring with a significantly increased frequency in TCS patients.

In conclusion, although cardiovascular malformation is an uncommon clinical presentation in TCS, the prevalence of cardiovascular malformation significantly increases in TCS patients compared with the general population. The current systematic literature review suggests that the cardiovascular malformation found in patients with TCS is likely to present with a simple lesion and a low operative risk.

What is already known on this topic?

The prevalence of cardiovascular malformations in patients with TCS is low.

What this study adds?

1) Patients with TCS have a higher prevalence of cardiovascular malformations than the general population.

2) Cardiovascular malformation in a patient with TCS is most likely to present as a simple lesion such as atrial septal defect and patent ductus arteriosus.

Acknowledgements

The authors thank (a) the Center of Cleft Lip-Cleft Palate and Craniofacial Deformities, Khon Kaen University under Tawanchai Royal Grant Project for its

publication support (b) the Faculty of Medicine, Khon Kaen University for its support and (c) Mr. Bryan Roderick Hamman for assistance with the English-language presentation of the manuscript.

Potential conflicts of interest

The authors declare no conflicts of interest.

References

1. Trainor PA, Dixon J, Dixon MJ. Treacher Collins syndrome: etiology, pathogenesis and prevention. *Eur J Hum Genet* 2009;17:275-83.
2. Fazen LE, Elmore J, Nadler HL. Mandibulo-facial dysostosis. (Treacher-Collins syndrome). *Am J Dis Child* 1967;113:405-10.
3. Collins ET. Case with symmetrical congenital notches in the outer part of each lower lid and defective development of the malar bones. *Trans Ophthalmol Soc UK* 1900;20:190-210.
4. Franceschetti A, Klein D. The mandibulofacial dysostosis; a new hereditary syndrome. *Acta Ophthalmol (Copenh)* 1949;27:143-224.
5. Vincent M, Genevieve D, Ostertag A, Marlin S, Lacombe D, Martin-Coignard D, et al. Treacher Collins syndrome: a clinical and molecular study based on a large series of patients. *Genet Med* 2016;18:49-56.
6. Plomp RG, van Lieshout MJ, Joosten KF, Wolvius EB, van der Schroeff MP, Versnel SL, et al. Treacher Collins syndrome: A systematic review of evidence-based treatment and recommendations. *Plast Reconstr Surg* 2016;137:191-204.
7. The Treacher Collins Syndrome Collaborative Group. Positional cloning of a gene involved in the pathogenesis of Treacher Collins syndrome. *Nat Genet* 1996;12:130-6.
8. Dauwerse JG, Dixon J, Seland S, Ruivenkamp CA,

- van Haeringen A, Hoefsloot LH, et al. Mutations in genes encoding subunits of RNA polymerases I and III cause Treacher Collins syndrome. *Nat Genet* 2011;43:20-2.
9. Schaefer E, Collet C, Genevieve D, Vincent M, Lohmann DR, Sanchez E, et al. Autosomal recessive *POLR1D* mutation with decrease of *TCOF1* mRNA is responsible for Treacher Collins syndrome. *Genet Med* 2014;16:720-4.
 10. Splendore A, Jabs EW, Passos-Bueno MR. Screening of *TCOF1* in patients from different populations: confirmation of mutational hot spots and identification of a novel missense mutation that suggests an important functional domain in the protein treacle. *J Med Genet* 2002;39:493-5.
 11. Giabicani E, Lemale J, Dainese L, Boudjema S, Coulomb A, Tounian P, et al. Chronic intestinal pseudo-obstruction in a child with Treacher Collins syndrome. *Arch Pediatr* 2017;24:1000-4.
 12. Hao S, Jin L, Wang H, Li C, Zheng F, Ma D, et al. Mutational analysis of *TCOF1*, *GSC*, and *HOXA2* in patients with Treacher Collins syndrome. *J Craniofac Surg* 2016;27:e583-6.
 13. Wang Y, Yin XJ, Han T, Peng W, Wu HL, Liu X, et al. A novel silent deletion, an insertion mutation and a nonsense mutation in the *TCOF1* gene found in two Chinese cases of Treacher Collins syndrome. *Mol Genet Genomics* 2014;289:1237-40.
 14. Zhang X, Fan Y, Zhang Y, Xue H, Chen X. A novel mutation in the *TCOF1* gene found in two Chinese cases of Treacher Collins syndrome. *Int J Pediatr Otorhinolaryngol* 2013;77:1410-5.
 15. Bauer M, Saldarriaga W, Wolfe SA, Beckwith JB, Frias JL, Cohen MM Jr. Two extraordinarily severe cases of Treacher Collins syndrome. *Am J Med Genet A* 2013;161A:445-52.
 16. Ulusal S, Gurkan H, Vatansever U, Kurkcü K, Tozkir H, Acunas B. A case of treacher collins syndrome. *Balkan J Med Genet* 2013;16:77-80.
 17. Marszalek-Kruk BA, Wojcicki P, Smigiel R, Trzeciak WH. Novel insertion in exon 5 of the *TCOF1* gene in twin sisters with Treacher Collins syndrome. *J Appl Genet* 2012;53:279-82.
 18. Li C, Mernagh J, Bourgeois J. Novel craniofacial and extracraniofacial findings in a case of Treacher Collins syndrome with a pathogenic mutation and a missense variant in the *TCOF1* gene. *Clin Dysmorphol* 2009;18:63-6.
 19. Writzl K, Jeruc J, Oldridge M, Peterlin B, Hennekam RC. Genital anomalies in a patient with Treacher Collins syndrome. *Am J Med Genet A* 2008;146A:2169-71.
 20. Horiuchi K, Ariga T, Fujioka H, Kawashima K, Yamamoto Y, Igawa H, et al. Mutational analysis of the *TCOF1* gene in 11 Japanese patients with Treacher Collins Syndrome and mechanism of mutagenesis. *Am J Med Genet A* 2005;134:363-7.
 21. Teber OA, Gillissen-Kaesbach G, Fischer S, Bohringer S, Albrecht B, Albert A, et al. Genotyping in 46 patients with tentative diagnosis of Treacher Collins syndrome revealed unexpected phenotypic variation. *Eur J Hum Genet* 2004;12:879-90.
 22. Horiuchi K, Ariga T, Fujioka H, Kawashima K, Yamamoto Y, Igawa H, et al. Treacher Collins syndrome with craniosynostosis, choanal atresia, and esophageal regurgitation caused by a novel nonsense mutation in *TCOF1*. *Am J Med Genet A* 2004;128A:173-5.
 23. Dinlen N, Zenciroglu A, Dilli D, Aydin B, Beken S, Okumus N. Treacher Collins syndrome with multiple congenital heart defects after paroxetine exposure: case report. *Genet Couns* 2014;25:7-11.
 24. Dobrilovic N, Fernandez AB, Lin A, Singh AK. Treacher Collins syndrome: sinus of Valsalva aneurysm. *Circulation* 2013;128:e12-3.
 25. Albarran AA, Carnero-Alcazar M, Maroto Castellanos LC, Rodriguez Hernandez JE. Giant aneurysm of the non-coronary sinus of Valsalva. *Eur J Cardiothorac Surg* 2013;43:649.
 26. Tsitouridis I, Bintoudi A, Diamantopoulou A, Michaelides M. Treacher-collins syndrome and associated abnormalities. A case report. *Neuroradiol J* 2007;20:365-72.
 27. Gottsegen G, Matheides P, Romoda T. Ventricular septal defect with mandibulofacial dysostosis. *Z Kreislaufforsch* 1956;45:499-503.
 28. Panamonta V, Wichajarn K, Chaikitpinoy A, Panamonta M, Pradubwong S, Chowchuen B. Birth prevalence of chromosome 22q11.2 deletion syndrome: A systematic review of population-based studies. *J Med Assoc Thai* 2016;99 Suppl 5:S187-93.
 29. Panamonta M, Chaikitpinoy A, Wongswadiwat Y, Soukkaseum C, Panamonta O, Wichajarn K. Cardiovascular malformations in patients with Oculo-Auriculo-Vertebral Spectrum: A systematic review. *J Med Assoc Thai* 2017;100 Suppl 6:S283-91.
 30. Panamonta V, Pradubwong S, Panamonta M, Chowchuen B. Prevalence of congenital heart diseases in patients with orofacial clefts: A systematic review. *J Med Assoc Thai* 2015;98 Suppl 7:S22-7.

รูปร่างของหัวใจและหลอดเลือดในผู้ป่วยกลุ่มอาการ Treacher Collins: ทบทวนอย่างเป็นระบบ

ณัฐ ปะนะมณฑา, อรรณิศา ไชกิจภิญโญ, ยุทธพงศ์ วงศ์สวัสดิวัฒน์, ภราดร จันทร์อ่อน, อวยพร ปะนะมณฑา, กุณฑล วิชาจารย์

ภูมิหลัง: รูปร่างของหัวใจและหลอดเลือดในผู้ป่วยกลุ่มอาการ Treacher Collins เป็นอาการที่อยู่นอกใบหน้าและศีรษะที่พบได้ไม่บ่อย และยังไม่มีการศึกษาทบทวนอย่างเป็นระบบ

วัตถุประสงค์: เพื่อศึกษาทบทวนอย่างเป็นระบบในรายงานความชุกและชนิดของรูปร่างของหัวใจและหลอดเลือดในผู้ป่วยกลุ่มอาการ Treacher Collins

วัสดุและวิธีการ: ค้นหาอย่างเป็นระบบในฐานข้อมูล PubMed, Google Scholar, Cochrane central data bases, และ OMIM ช่วงระหว่าง พ.ศ. 2539 ถึงเดือนมีนาคม พ.ศ. 2561 โดยใช้คำค้นว่า “Treacher Collins syndrome”

ผลการศึกษา: รายงานวิจัยที่เกี่ยวข้องมี 15 รายงานและมีผู้ป่วยกลุ่มอาการ Treacher Collins ทั้งหมด 159 ราย ในผู้ป่วยกลุ่มอาการนี้มีผู้ป่วย 144 (ร้อยละ 91) ราย ที่ตรวจพบความผิดปกติของ gene ร่วมด้วย [gene *TCOF1* (114 ราย), *POLRIC* (3 ราย), และ *POLRID* (27 ราย)] ในผู้ป่วย 144 ราย ที่ตรวจพบความผิดปกติของ gene ร่วมด้วย พบผู้ป่วยที่มีรูปร่างของหัวใจและหลอดเลือดจำนวน 8 (ร้อยละ 6) ราย ผู้ป่วยที่มีรูปร่างหัวใจและหลอดเลือดทั้ง 8 รายมีความผิดปกติของ gene *TCOF1* ชนิดเดียวกันนั้น ชนิดของรูปร่างหัวใจและหลอดเลือดที่พบคือ atrial septal defect (ASD) (5 ราย), patent ductus arteriosus (PDA) (2 ราย) และ ASD + PDA (1 ราย)

สรุป: ความชุกของรูปร่างของหัวใจและหลอดเลือดในผู้ป่วยกลุ่มอาการ Treacher Collins พบน้อยกว่าประชากรปกติทั่วไป และรูปร่างของหัวใจและหลอดเลือดที่พบในผู้ป่วยกลุ่มอาการ Treacher Collins ส่วนใหญ่เป็นความพิการแบบไม่ซับซ้อน
