



Urinary System Malformations in Patients with Treacher Collins syndrome: A Systematic Review

Suwannee Wisanuyotin MD¹, Patcharee Komvilaisak MD¹, Junya Jirapradittha MD¹,
Manat Panamonta MD¹, Ouyporn Panamonta MD¹, Khunton Wichajarn MD¹

¹ Department of Pediatrics, Faculty of Medicine, Khon Kaen University, Khon Kaen, Thailand

Background: Urinary system malformation is an uncommon extra-craniofacial anomaly in a patient with Treacher Collins syndrome [TCS]; notwithstanding, a systematic review of this manifestation is needed.

Objective: Our aim was to systematically review the prevalence and type of urinary malformations in patients with TCS.

Materials and Methods: A systematic literature search was conducted of PubMed Google Scholar, Cochrane central data bases, and OMIM, using the medical subject heading “Treacher Collins syndrome” for articles published between 1996 and March 2018.

Results: In the 15 studies identified, there were 159 patients with clinical diagnoses of TCS; 144 (91%) of whom had been documented gene mutations [*TCOF1* (114 patients), *POLRIC* (3 patients), or *POLRID* (27 patients) genes]. Of the 144, three (2%) patients had urinary system malformations. All 3 patients with urinary system malformations had only the *TCOF1* gene mutation. The types of urinary system malformations were urinary system malformations with unspecified types (2 cases) and urinary tract dysfunction (1 case).

Conclusion: Urinary system malformation is an uncommon clinical presentation in a patient with TCS but this type of malformation should be considered and managed along with other craniofacial treatments.

Keywords: Treacher Collins syndrome, Treacher Collins-Franceschetti syndrome, Urinary system, Malformations, Frequency, Type, *TCOF1*, *POLRIC*, *POLRID*, Gene

J Med Assoc Thai 2018; 101 (Suppl. 5): S233-S237

Full text. e-Journal: <http://www.jmatonline.com>

Treacher Collins syndrome [TCS] (Online Mendelian Inheritance in Man [OMIM]: TCS-1: 154500, TCS-2: 613717, TCS-3: 248390)-sometimes known as Treacher Collins-Franceschetti syndrome-is a craniofacial malformation syndrome resulting from developmental disorders of the first and second pharyngeal arches⁽¹⁾, and occurs in approximately 1 in 50,000 live-births^(1,2). It is the most common craniosynostosis anomaly^(1,2). The syndrome has been named after Dr. Edward Treacher Collins⁽³⁾ and

Dr. Adolphe Franceschetti⁽⁴⁾ who initially described this syndrome^(3,4). The most frequent abnormalities include downward slanting of the palpebral fissures, malar and mandibular hypoplasia, coloboma of the lower eye lid, microtia, and conductive hearing loss^(1,5). Frequently associated malformations include dental abnormalities, projection of the scalp hair into the lateral cheek, and cleft palate^(1,5).

A clinical diagnosis of TCS is based on the characteristic craniofacial anomalies^(3,4). Since 1996, mutation abnormalities of three genes [*TCOF1* (TCS1, location: in chromosome 5, autosomal dominant inheritance), *POLRID* (TCS2, location: in chromosome 13, autosomal dominant or autosomal recessive inheritances) and *POLRIC* (TCS3, location: in chromosome 6, autosomal recessive)] have been

Correspondence to:

Panamonta M, Department of Pediatrics, Faculty of Medicine, Khon Kaen University, Khon Kaen 40002, Thailand.

Phone: +66-81-7683538; **Fax:** +66-43-348382

E-mail: manat@kku.ac.th

How to cite this article: Wisanuyotin S, Komvilaisak P, Jirapradittha J, Panamonta M, Panamonta O, Wichajarn K. Urinary System Malformations in Patients with Treacher Collins syndrome: A Systematic Review. J Med Assoc Thai 2018;101;Suppl. 5: S233-S237.

identified in the majority of patients with craniofacial anomalies compatible with TCS⁽⁶⁻¹⁰⁾. The *TCOF1*, *POLRIC*, and *POLRID* genes have functions for ribosomal biogenesis, which are responsible for cell proliferation and cell growth⁽⁷⁻¹⁰⁾. Mutations of these genes result in defects in RNA biogenesis and abnormal ribosomal functions^(1,6-9). The spectrum of clinical presentations of TCS can be precisely determined with molecular assessment because patients with an atypical presentation can be included in the spectrum of this syndrome if they have any of the *TCOF1*, *POLRIC*, and *POLRID* gene mutations⁽⁶⁻¹⁰⁾.

Although craniofacial abnormalities are the most frequent clinical presentations of this syndrome, urinary system malformations of this syndrome are rare in patients with TCS^(5,8,9,11-22). As there has not yet been a systematic review of urinary system malformation of TCS, the authors summarized the reported prevalence and type of urinary system malformations in cohorts of patients with genetically-documented TCS.

Materials and Methods

Data sources

Molecular diagnosis of TCS genes began in 1996⁽⁷⁾, so a systematic literature search was conducted for articles on “Treacher Collins syndrome” published between January 1996 and March 2018. The search included PubMed, Google Scholar, Cochrane central data bases, and OMIM. Eligible papers in any language were included and screened. The titles and abstracts of the relevant articles were assessed independently by two authors (SW and MP) to identify potential articles for which full text publications were retrieved. Reference lists of included articles were examined for additional relevant articles that may have been missed in the search. This review protocol was done according to the PRISMA guideline.

Definitions

Urinary (renal) system malformations were defined as defects in the structure and function of the kidneys, ureters, bladder, and urethra, which produce, store, and eliminate urine.

TCS was defined as the most frequent craniofacial abnormality including downward slanting of palpebral fissures, malar and mandibular hypoplasia, coloboma of lower eyelids, microtia, and conductive hearing loss. Additionally, a molecular genetic assessment was used to confirm the diagnosis of TCS (i.e., a mutation in the *TCOF1*, *POLRIC* and *POLRID* genes).

Study selection

All published papers and case reports of patients with TCS, who had a molecular diagnosis of the *TCOF1*, *POLRIC* and *POLRID* genes, were considered for inclusion. Any reports that presented only clinical features without gene confirmations data were excluded. The authors also excluded reports which presented only clinical features without confirmational gene data.

Data extraction

From each research article, data were extracted on the total number of (a) patients with a clinical diagnosis of TCS, (b) patients with an identified gene mutation, (c) cases with urinary system malformations, and (d) types of urinary system malformations.

Quality assessment

Studies were assessed for completeness of data. Each study was evaluated with its molecular documentation.

Statistical analysis

The frequencies of urinary system malformations in TCS were reported as a percentage.

Results

The search combination in the databases identified 14,775 relevant articles. After thorough evaluations-using the study selection criteria-of these titles and abstracts, the authors excluded 14,760 articles. Therefore, only 15 articles met the study selection criteria and were extensively reviewed. After critical review of the full texts, one article was excluded due to incomplete data. Of these 14 articles left, there was one additional study found after reference checking. This additional study was not initially retrieved by the original search because it was not indexed in the searched databases. In the end, 15 articles were eligible for inclusion in the systematic review (Figure 1).

From among the 15 studies included, there were 159 patients who had a clinical diagnosis of TCS and 144 (91%) of these patients had documented gene mutations [*TCOF1* (114 patients), *POLRIC* (3 patients), or *POLRID* (27 patients) genes]. Of the 144 patients with gene-confirmed TCS, 3 (2%) patients had urinary system malformations (Table 1). All 3 patients with urinary system malformations had only *TCOF1* gene mutations. The type of urinary system malformations were urinary system malformations with unspecified types (2 cases) and urinary tract dysfunction (1 case)

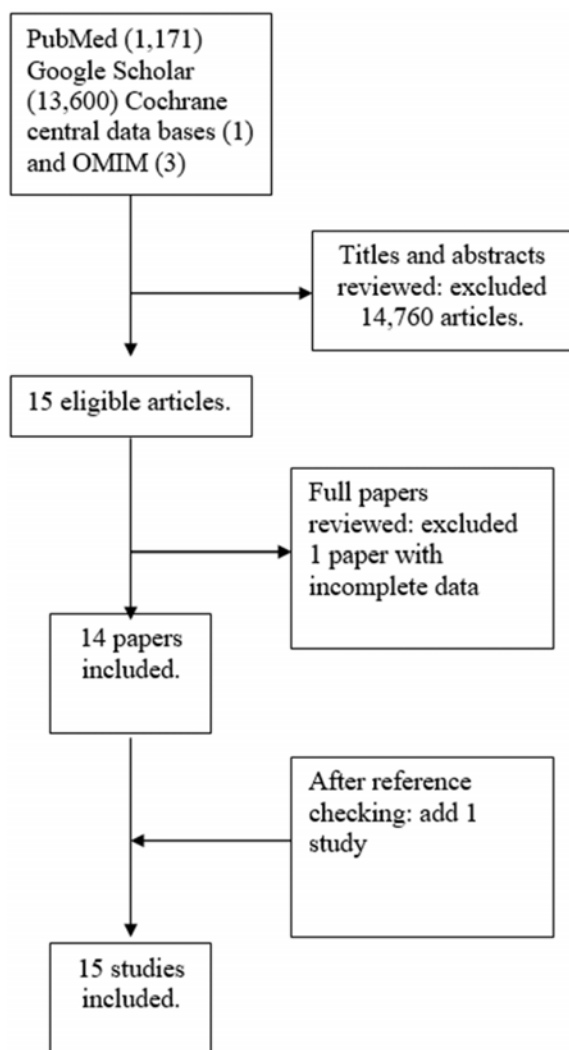


Figure 1. Flow diagram of the articles included into the systematic review.

(Table 1).

Discussion

In the current systematic review, the authors analyzed the magnitude of urinary system involvement in patients with molecular gene-confirmed TCS which had not been previously reported. The pooled average frequency of urinary system malformation was found in 2% of patients with TCS-confirmed through molecular gene study. From a prospective study, the congenital anomalies of kidneys and urinary tract [CAKUT] were found in 0.96% of infants using ultrasound screening⁽²³⁾. The authors did not make a comparison between the prevalence of urinary system malformation in patients

with TCS, and the prevalence of urinary system malformation in the general pediatric population, as the data came from different methodologies. Although urinary system malformation is uncommon in a patient with TCS, it should be carefully evaluated in each patient with a confirmed diagnosis of TCS. Thus, physicians providing care to patients with TCS should be aware of potential urinary system disorders associations.

TCS results from mutations in *TCOF1*, *POLR1C* or *POLR1D* genes, resulting in abnormal craniofacial development. A better understanding of the pathogenesis of the syndrome could help to identify the etiologies of varieties of urinary system malformations. Although some TCS patients may show apparent urinary system malformations, such presentations are sometimes overlooked.

Limitations of the current study lie in its methodology. The available studies are mostly small case series and case reports with small numbers of patients and/or lacking screening for extra-craniofacial features, as in the case of urinary system malformations. The methodology used to diagnose urinary system malformation is not always presented. The current literature review, however, provides comprehensive data suggesting that urinary system malformation can occur in TCS patients.

In conclusion, although a urinary system malformation is an uncommon presentation in TCS, the current systematic review of the literature suggests that this malformation may have to be managed during craniofacial treatments.

What is already known on this topic?

Urinary system malformations are uncommon presentations in patients with TCS.

What this study adds?

The prevalence of urinary system malformations in patients with gene-confirmed TCS was 2%.

Acknowledgements

The authors thank (a) the Center of Cleft Lip-Cleft Palate and Craniofacial Deformities, Khon Kaen University under Tawanchai Royal Grant Project for its publication support, and (b) Mr. Bryan Roderick Hamman for assistance with the English-language presentation of the manuscript.

Potential conflicts of interest

The authors declare no conflicts of interest.

Table 1. Frequency and type of urinary system malformations among the 144 patients with gene-mutation-confirmed Treacher Collins syndrome (TCS)

Authors/ Years	Numbers of patients with gene mutation identified/ Total numbers of patients with clinical diagnosis of TCS	Number of cases with urinary system malformations (N)			Number of cases with urinary system malformations (N)/ Total numbers of patients with gene-mutation confirmed TCS (%)	Types of urinary system malformations (N)
		N/ Number of patients with <i>TCOF1</i> gene mutation	N/ Number of patients with <i>POLRIC</i> gene mutation	N/ Number of patients with <i>POLRID</i> gene mutation		
Giabicani et al ⁽¹¹⁾ /2017	1/1	1/1 ^a	ND	ND	1/1 (100)	Urinary tract dysfunction ^b (1)
Vincent et al ⁽⁵⁾ /2016 ^d	65/70	2/60 ^c	ND	0/5 ^c	2/65 (3)	Urinary system malformations ^c (2)
Hao et al ⁽¹²⁾ /2016	3/3	0/3	ND	ND	0/3 (0)	NA
Wang et al ⁽¹³⁾ /2014	3/3	0/3	ND	ND	0/3 (0)	NA
Schaefer et al ⁽⁹⁾ /2014	2/2	0/0	ND	0/2	0/2 (0)	NA
Zhang et al ⁽¹⁴⁾ /2013	2/2	0/2	ND	ND	0/2 (0)	NA
Bauer et al ⁽¹⁵⁾ /2013	2/2	0/2	ND	ND	0/2 (0)	NA
Ulusal et al ⁽¹⁶⁾ /2013	1/1	0/1	ND	ND	0/1 (0)	NA
Marszalek-Kruk et al ⁽¹⁷⁾ /2012	2/2	0/2	ND	ND	0/2 (0)	NA
Dauwerse et al ⁽⁸⁾ /2011 ^d	23/23	ND	0/3	0/20	0/23 (0)	NA
Li et al ⁽¹⁸⁾ /2009	1/1	0/1	ND	ND	0/1 (0)	NA
Writzl et al ⁽¹⁹⁾ /2008	1/1	0/1	ND	ND	0/1 (0)	NA
Horiuchi et al ⁽²⁰⁾ /2005	9/11	0/9	ND	ND	0/9 (0)	NA
Teber et al ⁽²¹⁾ /2004 ^d	28/36	0/28	ND	ND	0/28 (0)	NA
Horiuchi et al ⁽²²⁾ /2004	1/1	0/1	ND	ND	0/1 (0)	NA
Total	144/159	3/114	0/3	0/27	3/144 (2)	Urinary tract dysfunction ^b (1), Urinary system malformations ^c (2)

TCS = Treacher Collins syndrome; N = numbers of cases; ND = not determined; NA = not available

^a Heterozygous deletion c.4369_4373 (p.Lys1457- Glufs*12) in exon 3 of *TCOF1* gene was identified in this patient and his father.

^b He had presented several urinary tract infections without pyelonephritis since the age of 7 years. Ultrasonography showed persistent sediment in the bladder, suggesting urinary tract dysfunction.

^c Types of urinary system malformations were not reported⁽⁵⁾.

^d Prospective studies.

References

1. Trainor PA, Dixon J, Dixon MJ. Treacher Collins syndrome: etiology, pathogenesis and prevention. *Eur J Hum Genet* 2009;17:275-83.
2. Fazen LE, Elmore J, Nadler HL. Mandibulo-facial dysostosis. (Treacher-Collins syndrome). *Am J Dis Child* 1967;113:405-10.
3. Collins ET. Case with symmetrical congenital notches in the outer part of each lower lid and defective development of the malar bones. *Trans Ophthalmol Soc UK* 1900;20:190-210.
4. Franceschetti A, Klein D. Mandibulo-facial dysostosis: new hereditary syndrome. *Acta Ophthalmol* 1949;27:143-224.
5. Vincent M, Genevieve D, Ostertag A, Marlin S, Lacombe D, Martin-Coignard D, et al. Treacher Collins syndrome: a clinical and molecular study based on a large series of patients. *Genet Med* 2016;18:49-56.
6. Plomp RG, van Lieshout MJ, Joosten KF, Wolvius EB, van der Schroeff MP, Versnel SL, et al. Treacher Collins Syndrome: A systematic review of evidence-based treatment and recommendations. *Plast Reconstr Surg* 2016;137:191-204.
7. The Treacher Collins Syndrome Collaborative Group. Positional cloning of a gene involved in the pathogenesis of Treacher Collins syndrome. *Nat Genet* 1996;12:130-6.
8. Dauwerse JG, Dixon J, Seland S, Ruivenkamp CA, van Haeringen A, Hoefsloot LH, et al. Mutations in genes encoding subunits of RNA polymerases I and III cause Treacher Collins syndrome. *Nat Genet* 2011;43:20-2.
9. Schaefer E, Collet C, Genevieve D, Vincent M, Lohmann DR, Sanchez E, et al. Autosomal recessive *POLR1D* mutation with decrease of *TCOF1* mRNA is responsible for Treacher Collins syndrome. *Genet Med* 2014;16:720-4.
10. Splendore A, Jabs EW, Passos-Bueno MR. Screening of *TCOF1* in patients from different populations: confirmation of mutational hot spots and identification of a novel missense mutation that suggests an important functional domain in the protein treacle. *J Med Genet* 2002;39:493-5.
11. Giabicani E, Lemale J, Dainese L, Boudjemaa S, Coulomb A, Tounian P, et al. Chronic intestinal pseudo-obstruction in a child with Treacher Collins syndrome. *Arch Pediatr* 2017;24:1000-4.
12. Hao S, Jin L, Wang H, Li C, Zheng F, Ma D, et al. Mutational analysis of *TCOF1*, *GSC*, and *HOXA2* in patients with Treacher Collins syndrome. *J Craniofac Surg* 2016;27:e583-6.
13. Wang Y, Yin XJ, Han T, Peng W, Wu HL, Liu X, et al. A novel silent deletion, an insertion mutation and a nonsense mutation in the *TCOF1* gene found in two Chinese cases of Treacher Collins syndrome. *Mol Genet Genomics* 2014;289:1237-40.
14. Zhang X, Fan Y, Zhang Y, Xue H, Chen X. A novel mutation in the *TCOF1* gene found in two Chinese cases of Treacher Collins syndrome. *Int J Pediatr Otorhinolaryngol* 2013;77:1410-5.
15. Bauer M, Saldarriaga W, Wolfe SA, Beckwith JB, Frias JL, Cohen MM Jr. Two extraordinarily severe cases of Treacher Collins syndrome. *Am J Med Genet A* 2013;161A:445-52.
16. Ulusal S, Gurkan H, Vatansver U, Kurkcu K, Tozkir H, Acunas B. A case of treacher collins syndrome. *Balkan J Med Genet* 2013;16:77-80.
17. Marszalek-Kruk BA, Wojcicki P, Smigiel R, Trzeciak WH. Novel insertion in exon 5 of the *TCOF1* gene in twin sisters with Treacher Collins syndrome. *J Appl Genet* 2012;53:279-82.
18. Li C, Mernagh J, Bourgeois J. Novel craniofacial and extracraniofacial findings in a case of Treacher Collins syndrome with a pathogenic mutation and a missense variant in the *TCOF1* gene. *Clin Dysmorphol* 2009;18:63-6.
19. Writzl K, Jeruc J, Oldridge M, Peterlin B, Hennekam RC. Genital anomalies in a patient with Treacher Collins syndrome. *Am J Med Genet A* 2008;146A:2169-71.
20. Horiuchi K, Ariga T, Fujioka H, Kawashima K, Yamamoto Y, Igawa H, et al. Mutational analysis of the *TCOF1* gene in 11 Japanese patients with Treacher Collins Syndrome and mechanism of mutagenesis. *Am J Med Genet A* 2005;134:363-7.
21. Teber OA, Gillissen-Kaesbach G, Fischer S, Bohringer S, Albrecht B, Albert A, et al. Genotyping in 46 patients with tentative diagnosis of Treacher Collins syndrome revealed unexpected phenotypic variation. *Eur J Hum Genet* 2004;12:879-90.
22. Horiuchi K, Ariga T, Fujioka H, Kawashima K, Yamamoto Y, Igawa H, et al. Treacher Collins syndrome with craniosynostosis, choanal atresia, and esophageal regurgitation caused by a novel nonsense mutation in *TCOF1*. *Am J Med Genet A* 2004;128A:173-5.
23. Caiulo VA, Caiulo S, Gargasole C, Chiriaco G, Latini G, Cataldi L, et al. Ultrasound mass screening for congenital anomalies of the kidney and urinary tract. *Pediatr Nephrol* 2012;27:949-53.

รูปร่างผิดปกติของระบบทางเดินปัสสาวะในผู้ป่วยกลุ่มอาการ Treacher Collins: ทบทวนอย่างเป็นระบบ

สุวรรณณี วิษณุโยธิน, พัชรี คำวิไลย์ศักดิ์, จรรยา จิระประดิษฐา, มนัส ปะนะมณฑา, อวยพร ปะนะมณฑา, กุณฑล วิชาจารย์

ภูมิหลัง: รูปร่างผิดปกติของระบบทางเดินปัสสาวะเป็นความพิการนอกใบหน้าและศีรษะที่พบได้ไม่บ่อยในผู้ป่วยที่มีกลุ่มอาการ Treacher Collins และยังไม่มีการศึกษาทบทวนอย่างเป็นระบบ

วัตถุประสงค์: เพื่อศึกษาทบทวนอย่างเป็นระบบในรายงานความชุกและชนิดของรูปร่างผิดปกติของระบบทางเดินปัสสาวะในผู้ป่วยกลุ่มอาการ Treacher Collins

วัสดุและวิธีการ: ค้นหาอย่างเป็นระบบในฐานข้อมูล PubMed, Google scholar, Cochrane central data bases, และ OMIM ที่รายงานระหว่าง พ.ศ. 2539 ถึง มีนาคม พ.ศ. 2561 โดยใช้คำค้นว่า “Treacher Collins syndrome”

ผลการศึกษา: จากการรวบรวมงานวิจัย 15 รายงาน พบผู้ป่วยที่ได้รับการวินิจฉัยทางคลินิกว่าเป็นกลุ่มอาการ Treacher Collins 159 ราย และมีผู้ป่วย 144 (ร้อยละ 91) ราย ที่ตรวจพบความผิดปกติของ gene [ได้แก่ TCOF1 (114 ราย), POLRIC (3 ราย), และ POLRID (27 ราย)] ในผู้ป่วยที่มีความผิดปกติของ gene 144 ราย มีผู้ป่วย 3 (ร้อยละ 2) ราย ที่มีรูปร่างผิดปกติของระบบทางเดินปัสสาวะร่วมด้วย ผู้ป่วยที่มีรูปร่างผิดปกติของระบบทางเดินปัสสาวะทั้ง 3 ราย มีความผิดปกติของ gene TCOF1 ชนิดของรูปร่างผิดปกติของระบบทางเดินปัสสาวะที่พบคือรูปร่างผิดปกติของระบบทางเดินปัสสาวะที่ไม่ได้บอกชนิด 2 ราย และการทำงานที่ผิดปกติของระบบทางเดินปัสสาวะอีก 1 ราย

สรุป: รูปร่างผิดปกติของระบบทางเดินปัสสาวะพบได้ไม่บ่อยในผู้ป่วยกลุ่มอาการ Treacher Collins แต่ควรตรวจหาความผิดปกติของระบบทางเดินปัสสาวะที่อาจพบร่วมด้วย และบำบัดรักษา ร่วมกับการรักษาความพิการทางใบหน้าและศีรษะในผู้ป่วยกลุ่มอาการ Treacher Collins
